



SSS Fırsatçı Enfeksiyonlarında Nöroradyolojik Yaklaşım

Prof.Dr.Gül Hatipoğlu
Sağlık Bilimleri Üniversitesi
Ankara Bilkent Şehir Hastanesi

21 Mayıs 2024

BAĞIŞIKLIK SİSTEMİ BASKILANMIŞ HASTALAR

- İleri yaşta diabet gibi kronik hastalığı olan hastalar
- Kanser hastaları
- HIV hastaları
- İlaç Kullanımı

53 y e

6 gündür sağ tarafta güçsüzlük

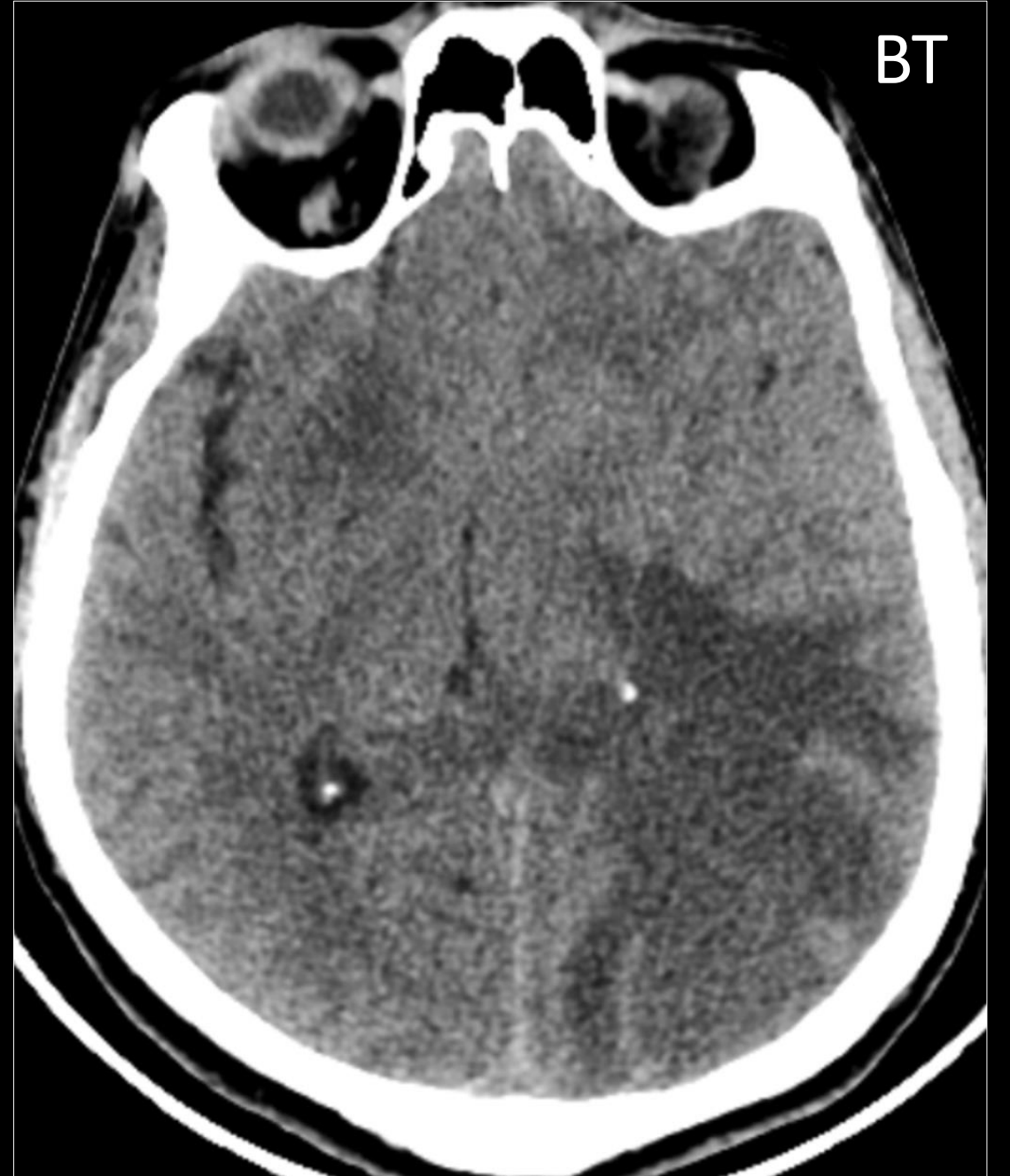Bilinç bulanıklığı ile acil servise getiriliyor

Beyin BT'sinde ödem saptanması nedeniyle

LP yapılamıyor

Bilgisayarlı Tomografi-BT

- Beyin dansitesini deęerlendirir
- Hızlı ve kolay erişim
- Tarama amaçlı
 - Hemoraji
 - Herniasyon
 - Hidrosefali
 - Ödem/kitle etkisi
- Kontrast nadiren faydalı
 - Hastalar nasılsa MR'a gidecek



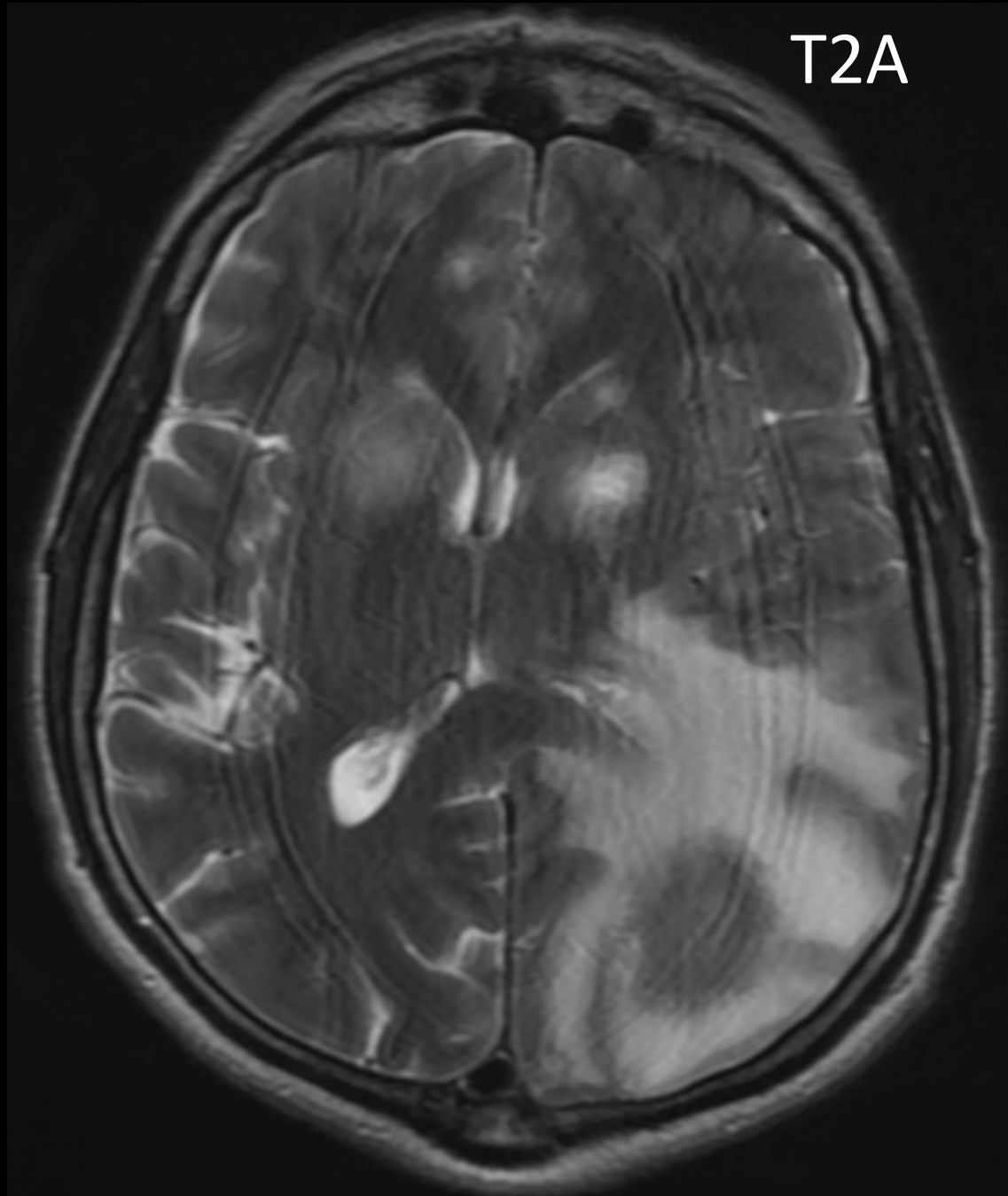
MR Sekansları-T2

Suya hassas

- BOS parlak
- T2 Hiperintens
 - Ödem
- Bazı özel durumlar

T2 Hipointens

- Apse duvarı
- Tüberküloz
- Lenfoma



FLAIR

MR Sekansları-FLAIR

Fluid Attenuated Inversion Recovery

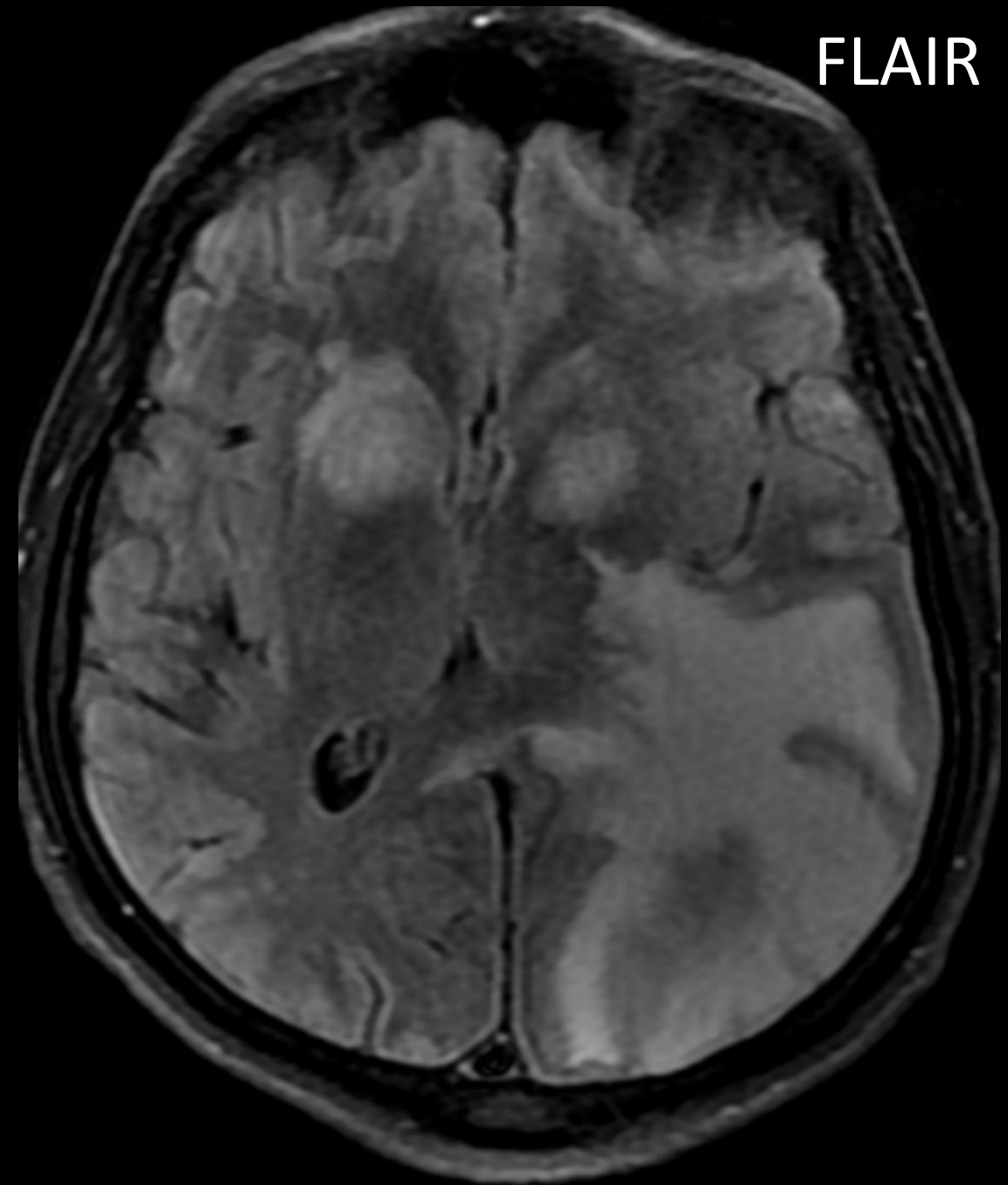
BOS baskılanır

Hiperintens

➤ Ödem

➤ Kan

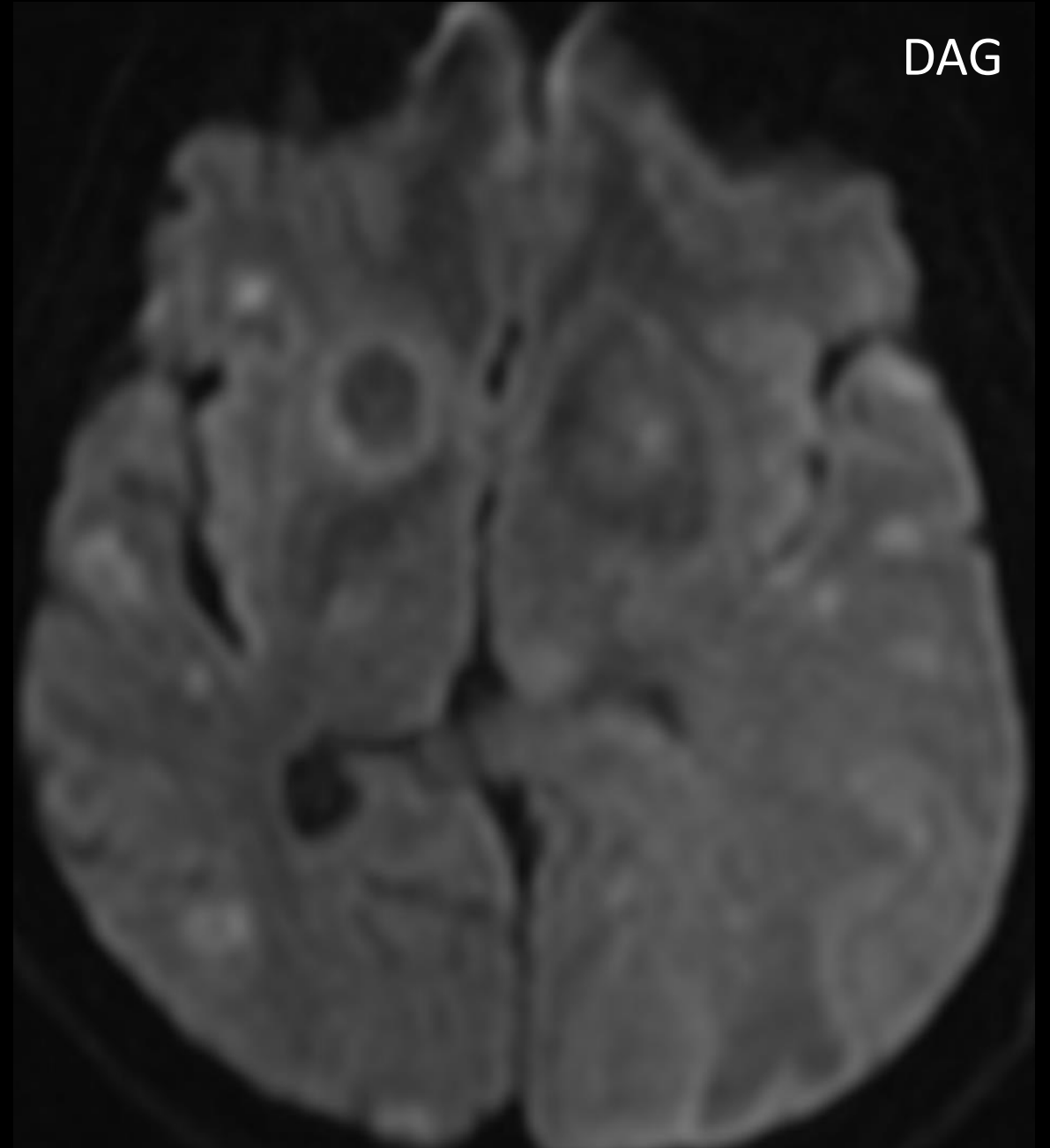
➤ Püy



MR Sekansları-DAG

Difüzyon Ağırlıklı Görüntüleme

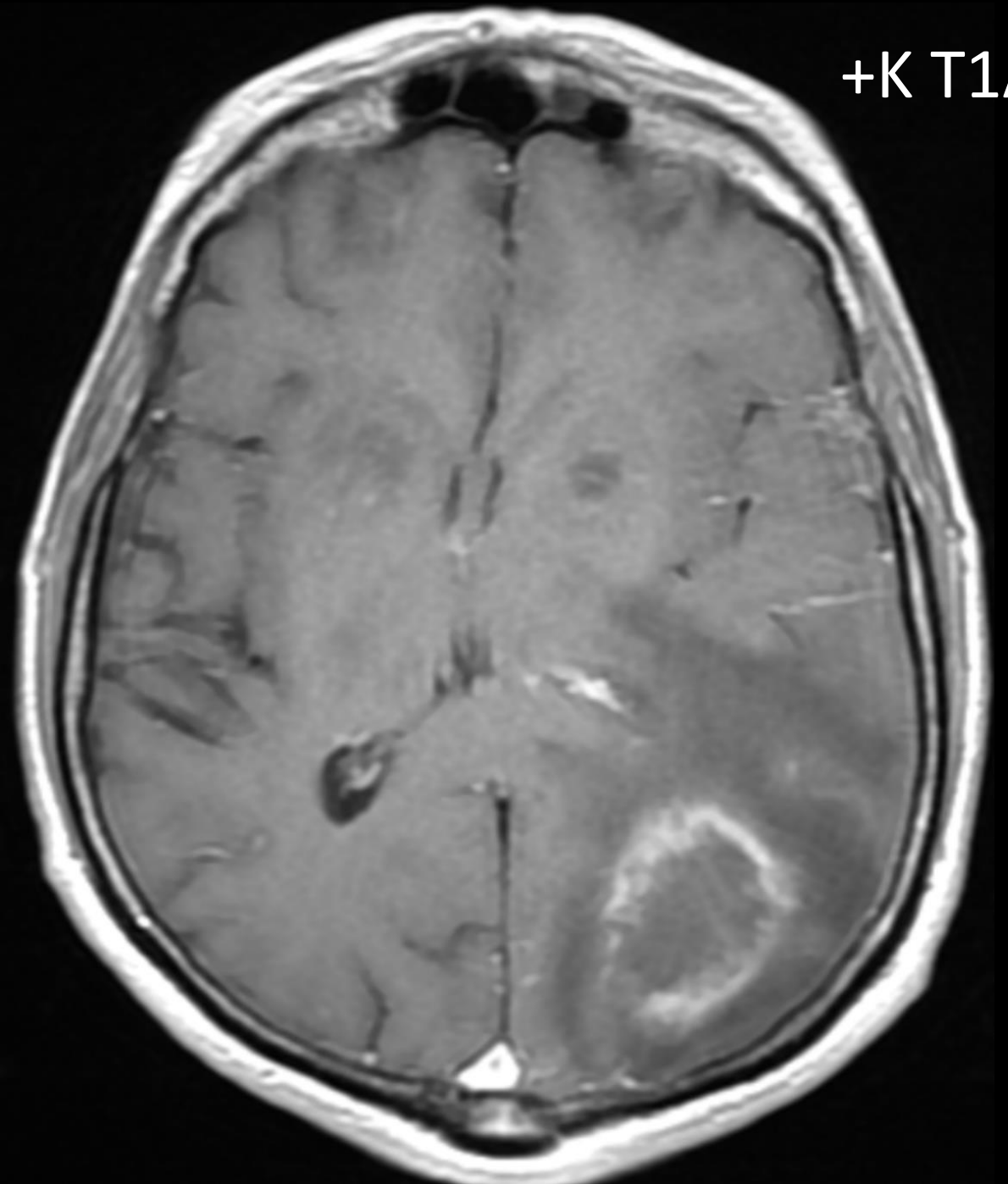
- Serbest su protonlarının hareketi
- Hiperintens
 - İnme
 - Kan
 - PÜY



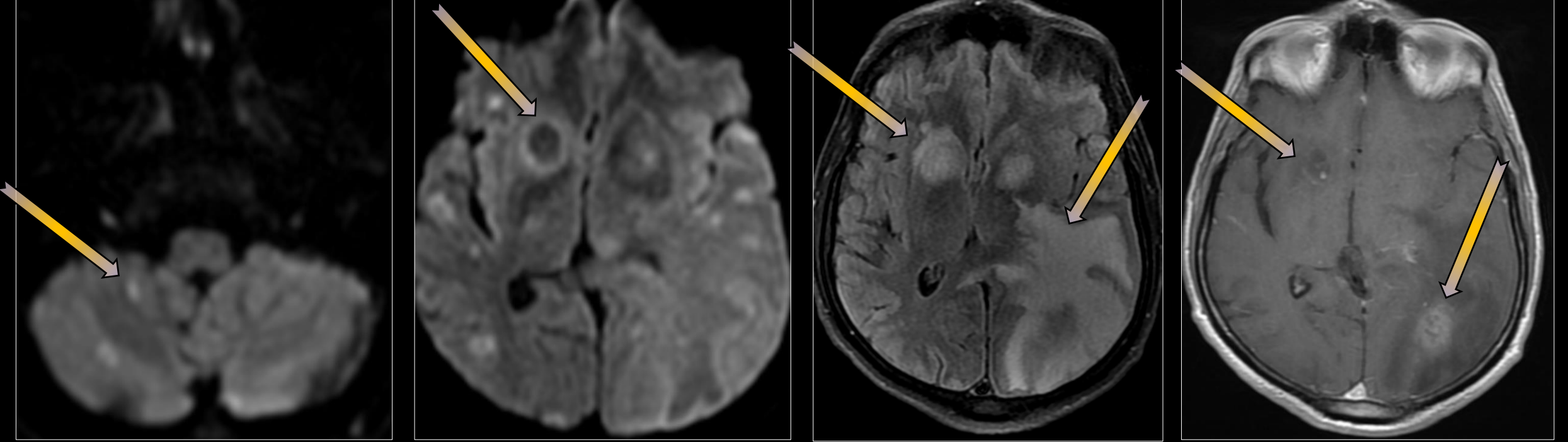
+K T1A

MR sekansları-T1 postkontrast

- Kontrastlanma
 - KBB bozulduğu alanlar
 - Kontrastlanan kitle
 - Leptomeningeal kontrastlanma

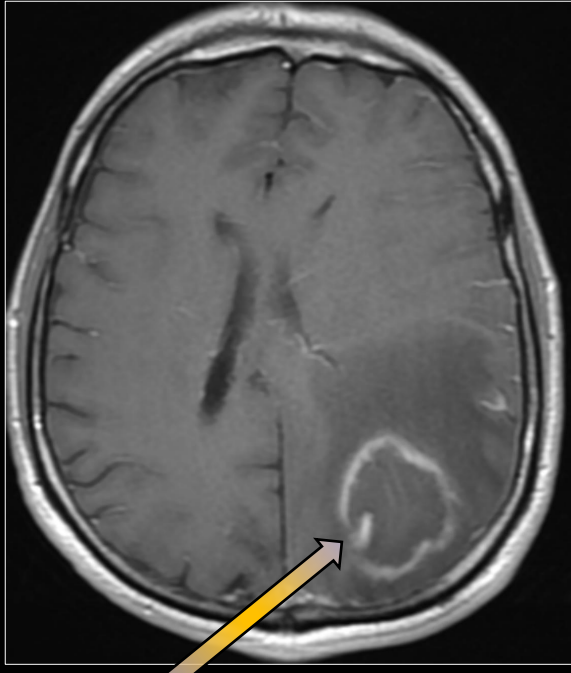
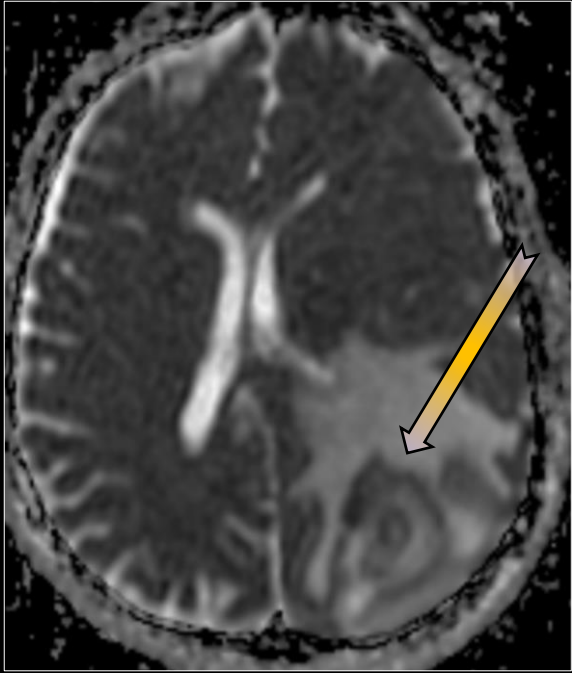
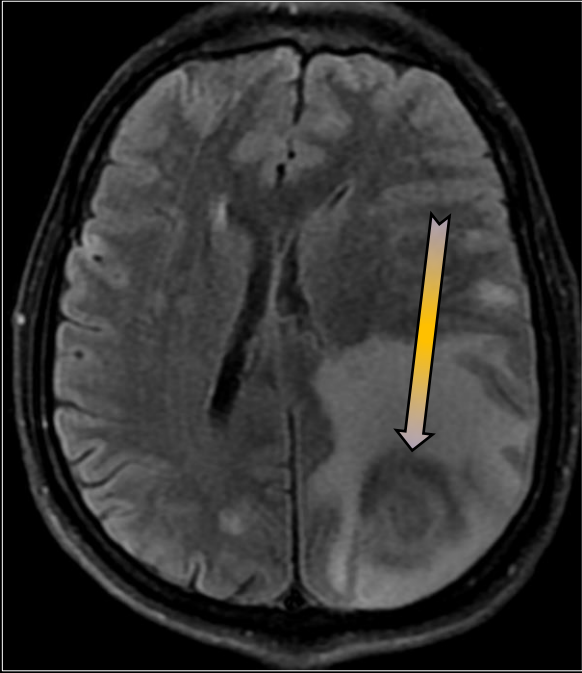
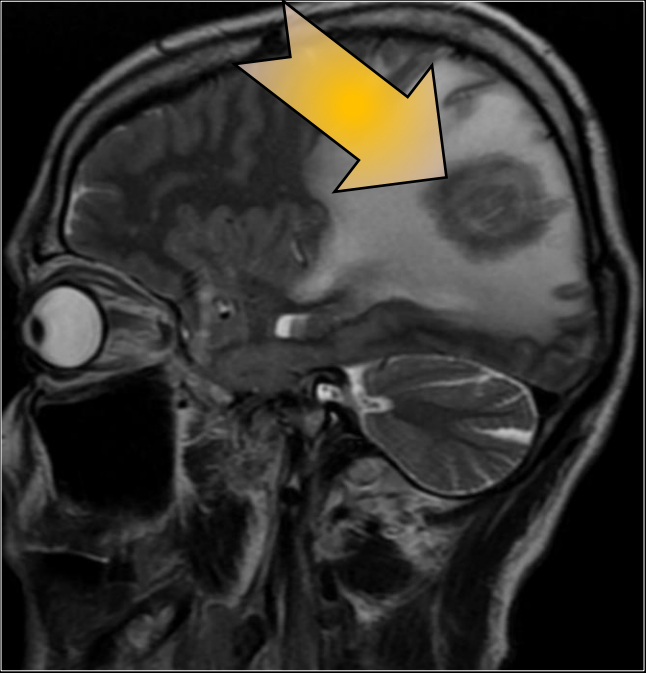


1.Toksoplazmozis

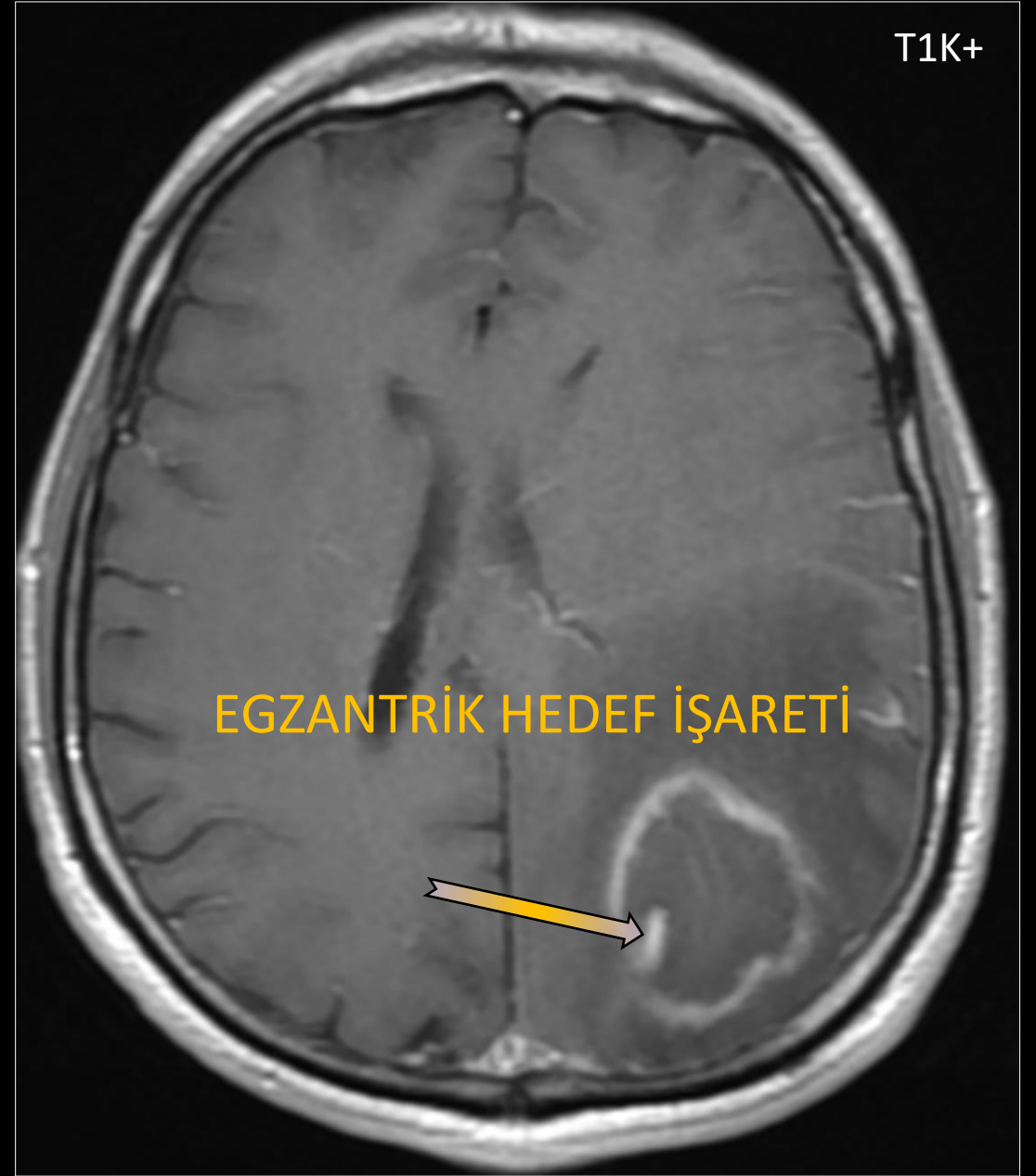
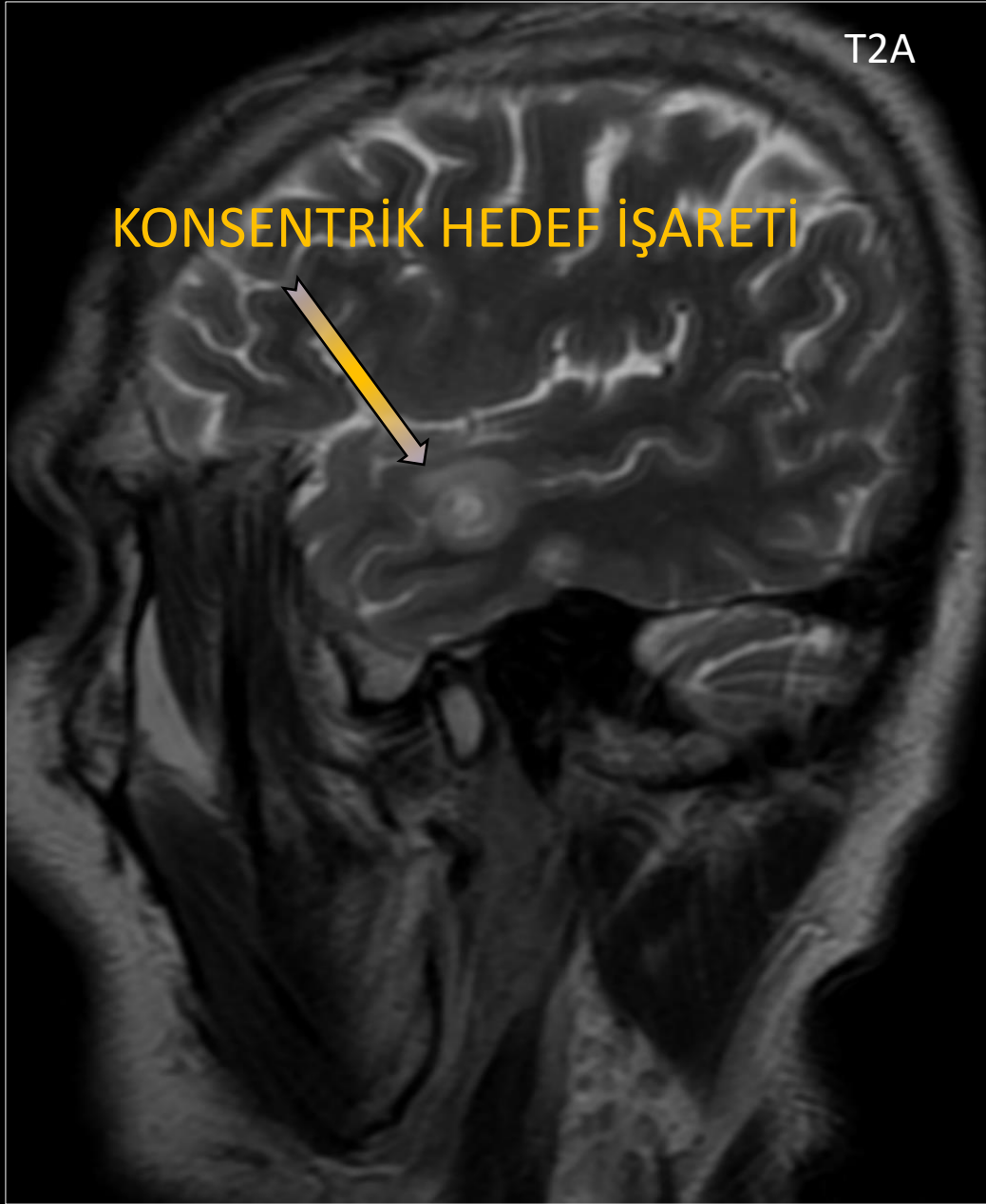


53y e, bilinen bir hastalığı yok, sağ tarafında güçsüzlük ve bilinç bulanıklığı ile acile getiriliyor.

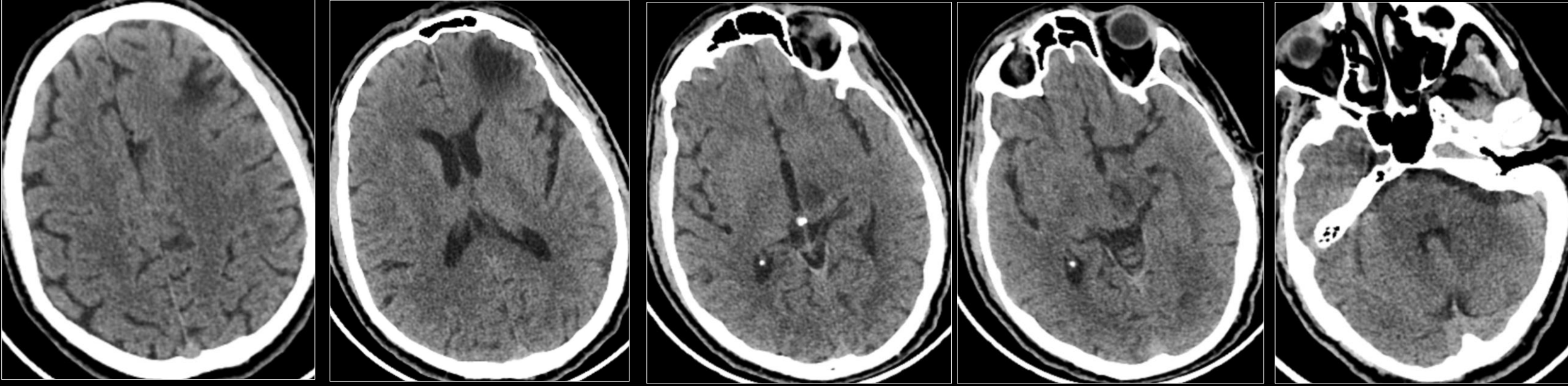
53y e



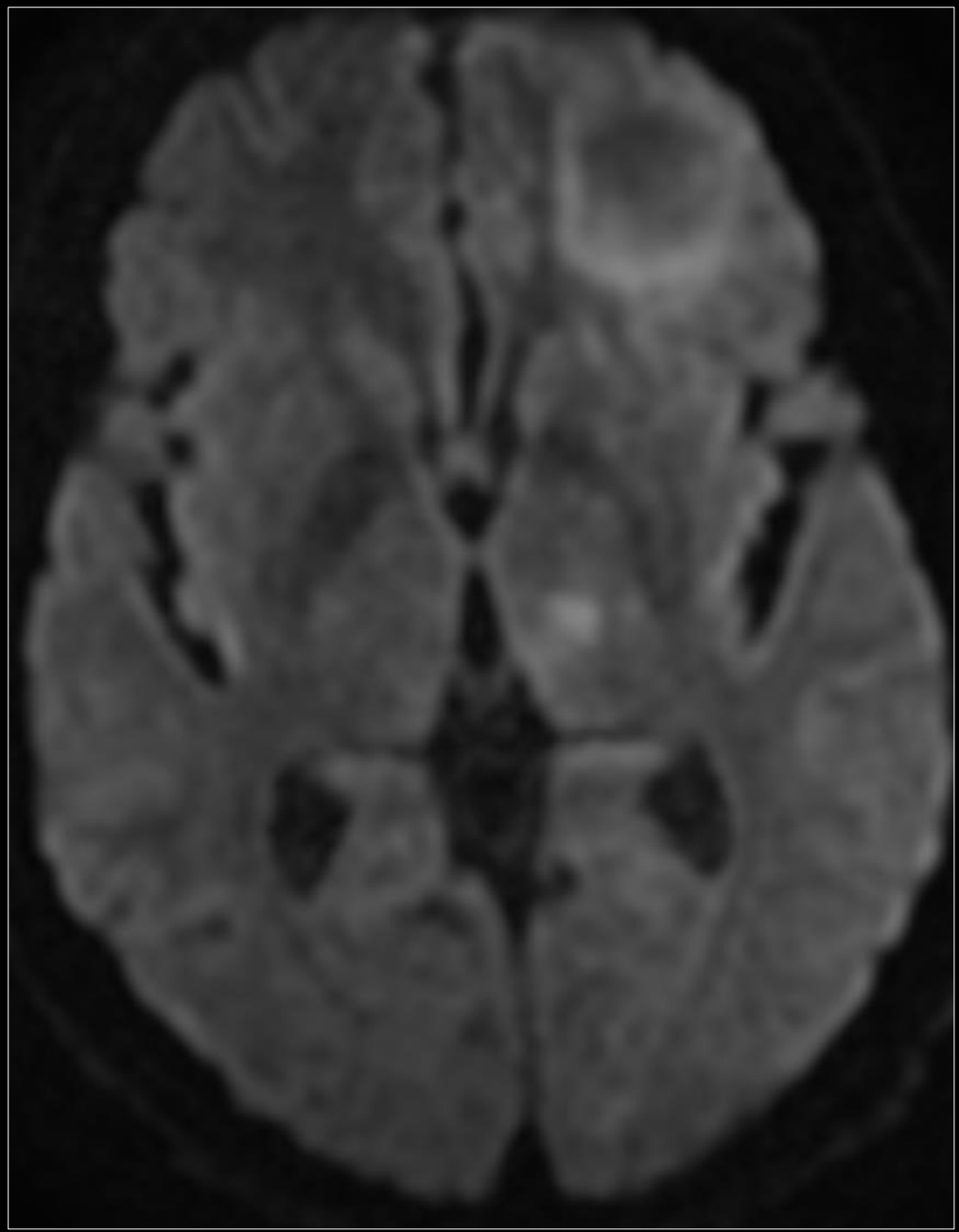
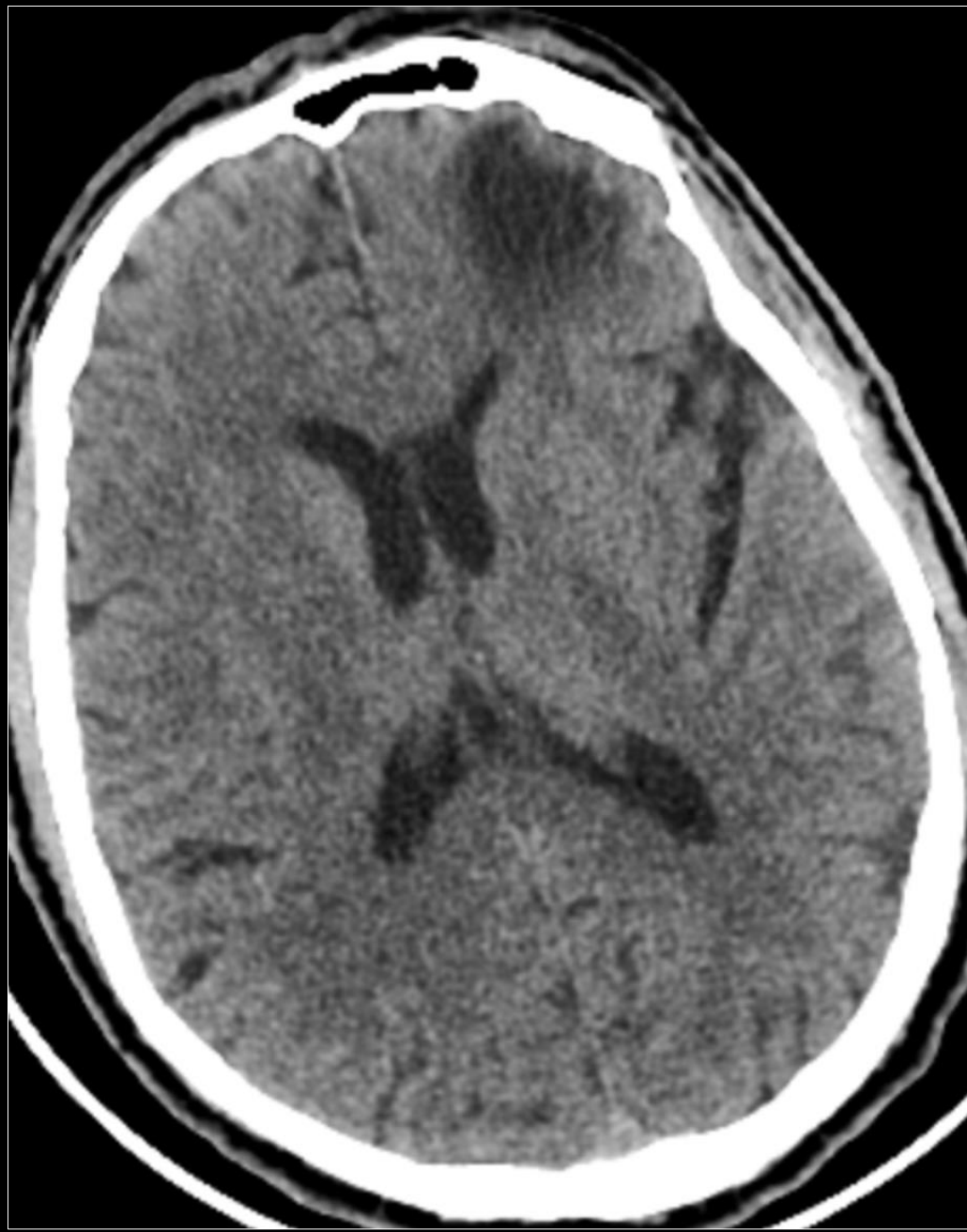53y e

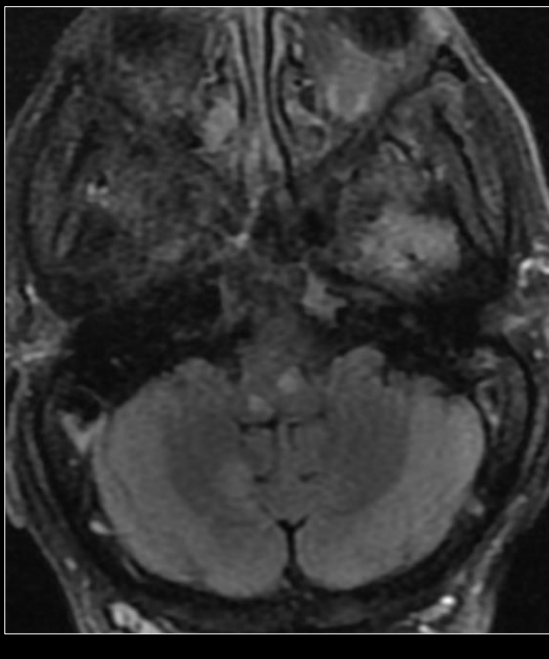
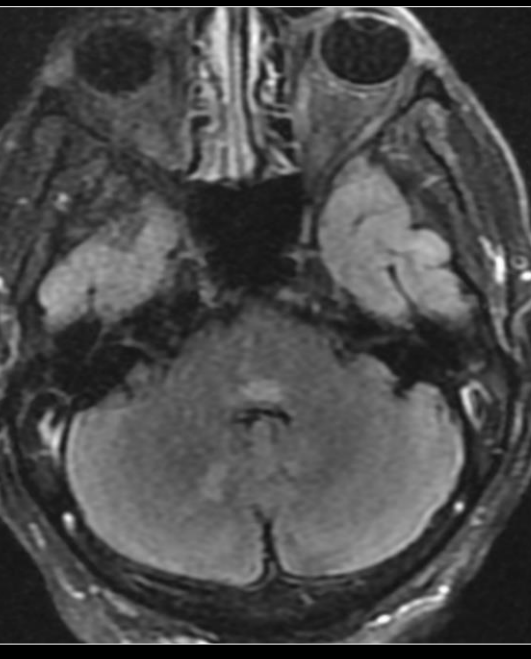
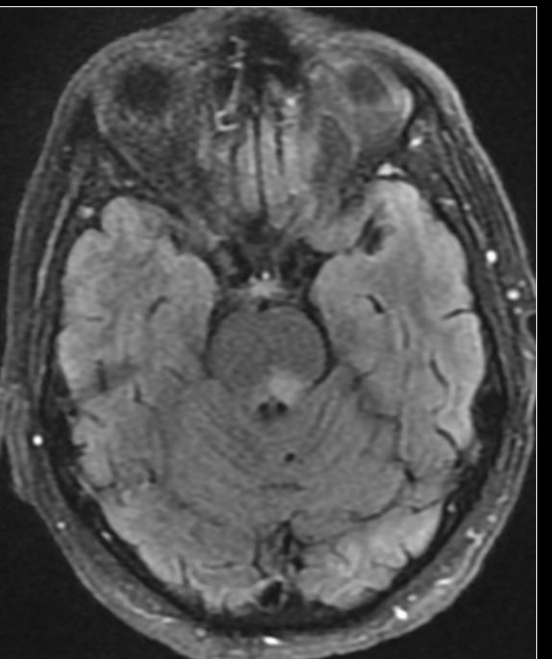
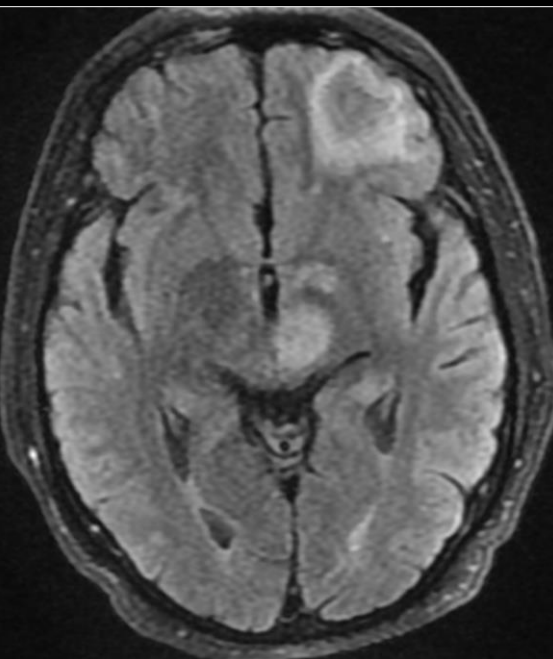
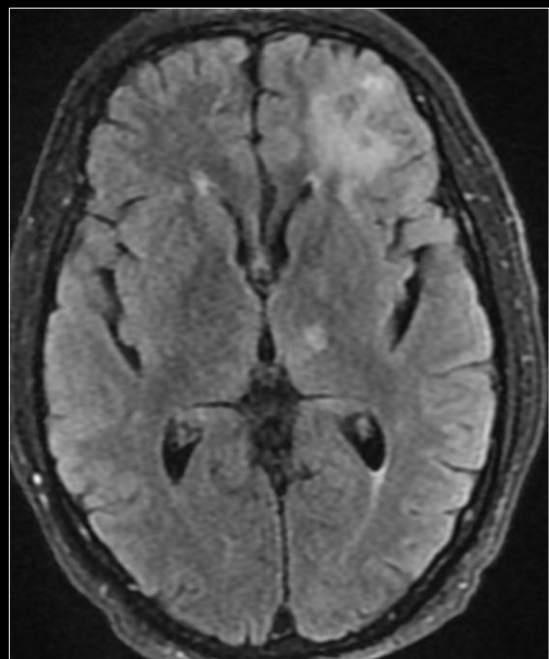
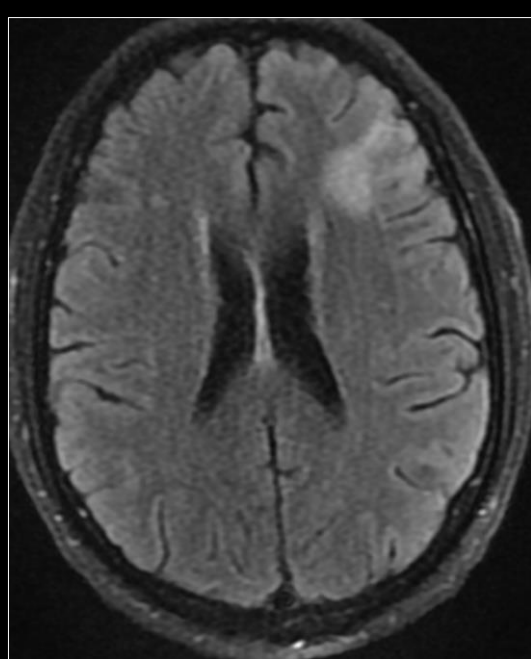
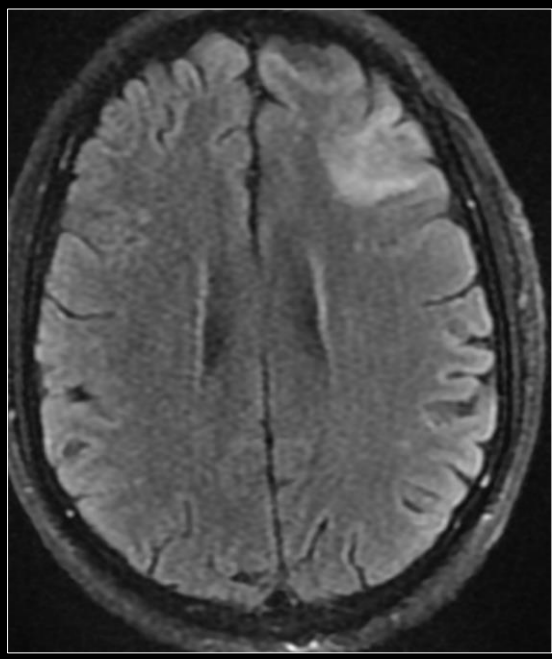
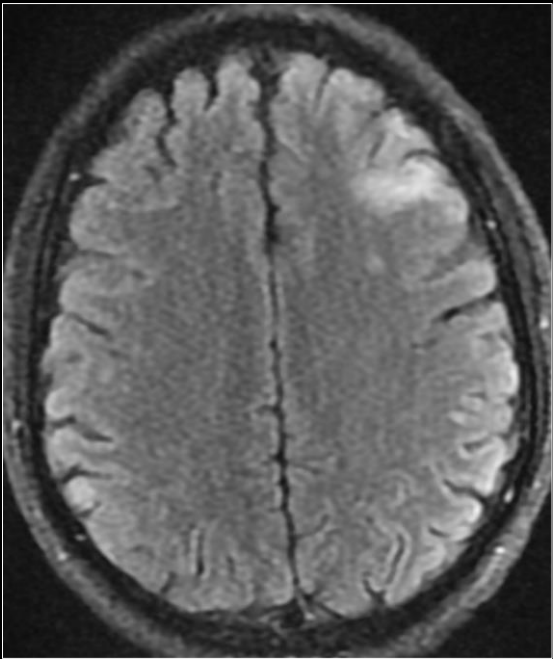


2. Progresif Multifokal L koensefalopati



56y e, sol tarafta gelişen güçsüzlük nedeniyle acil servise başvuruyor.

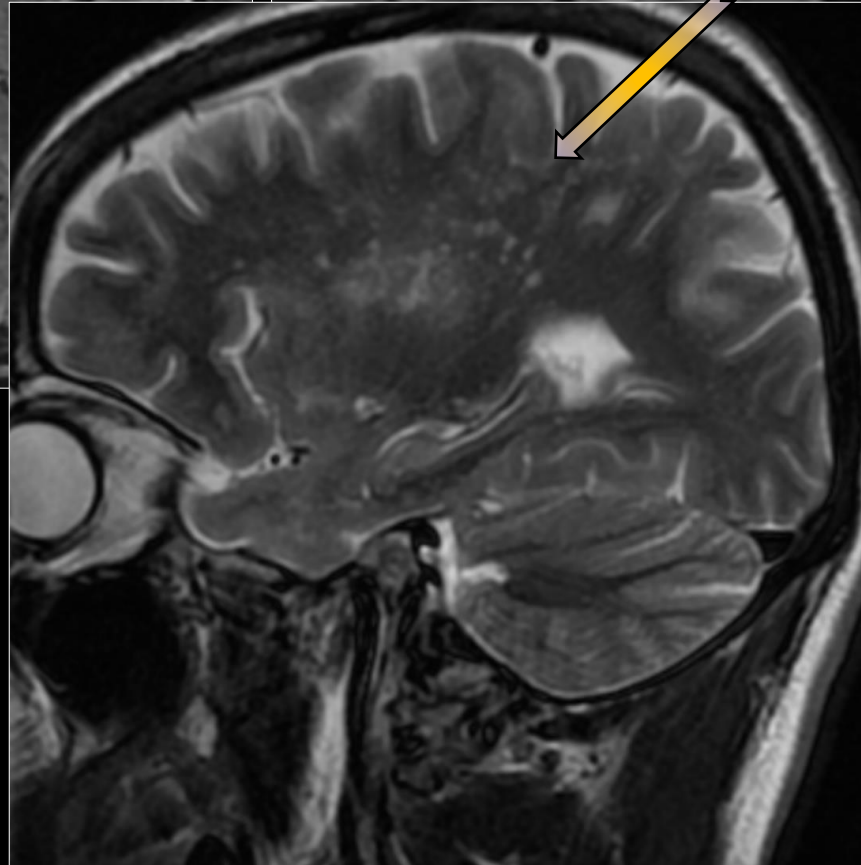
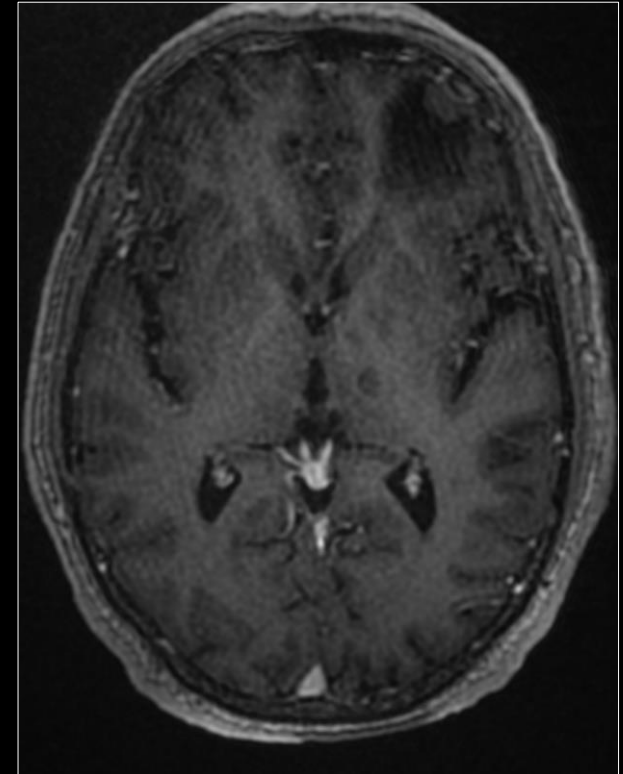
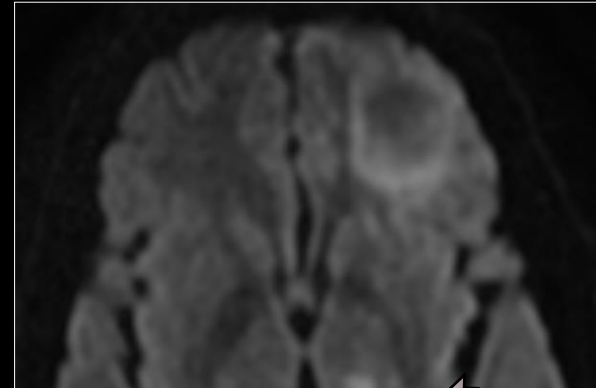
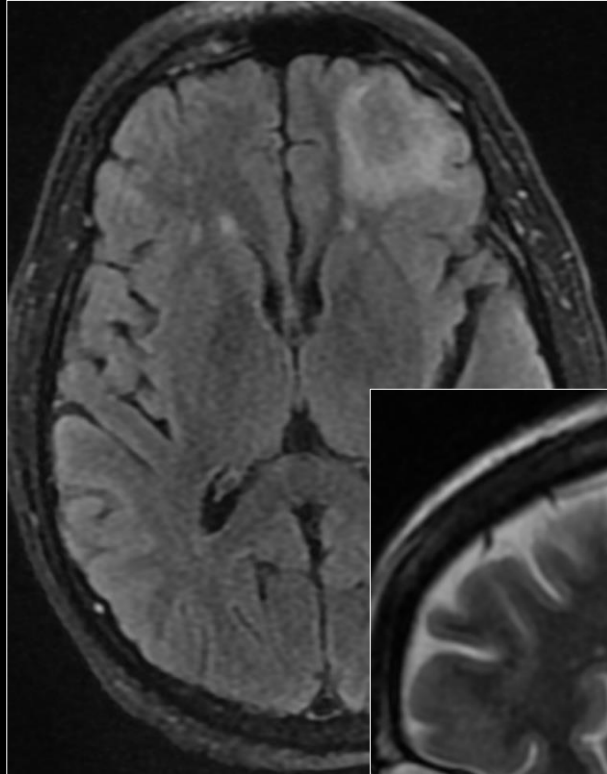
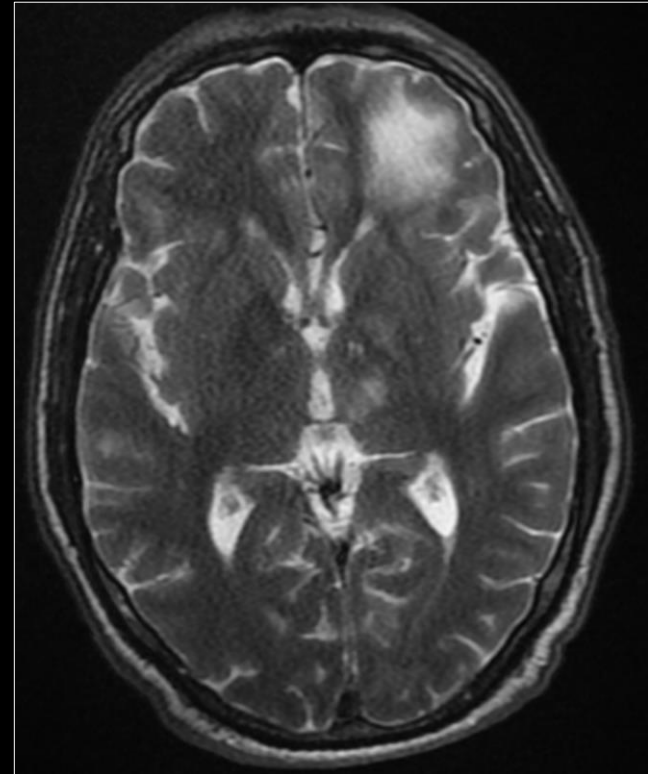




T2/FLAIR UYUMSUZLUĐU

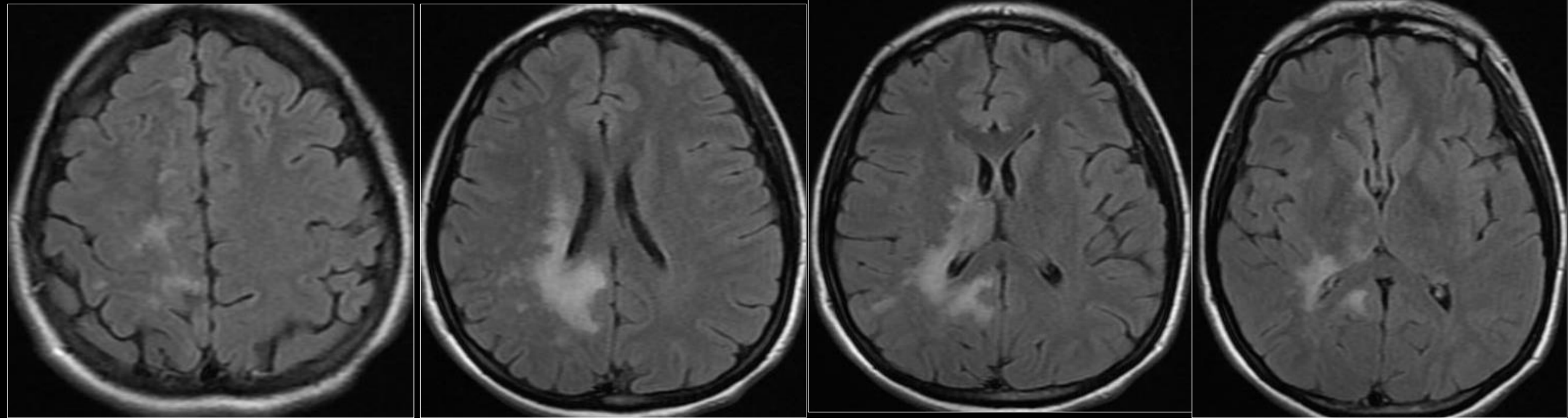
PERİFERAL KISITLANMA

KONTRASTLANMAZ

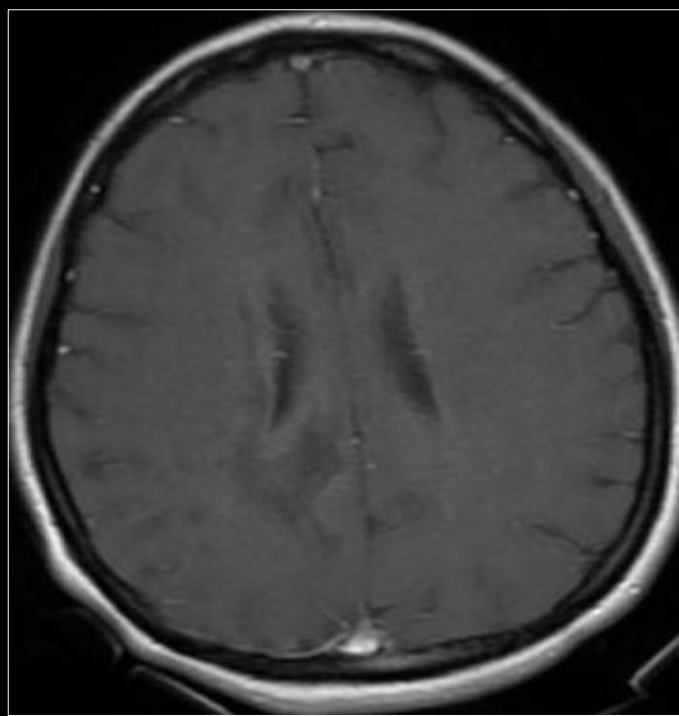
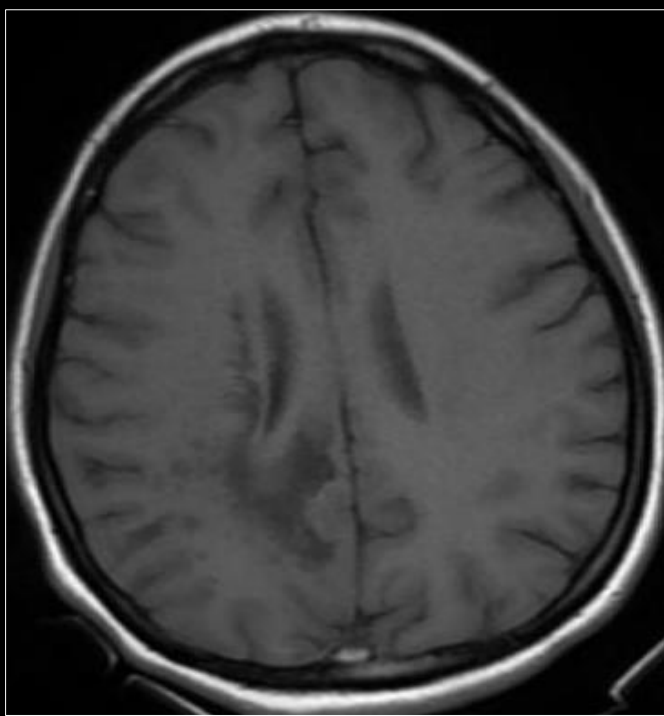
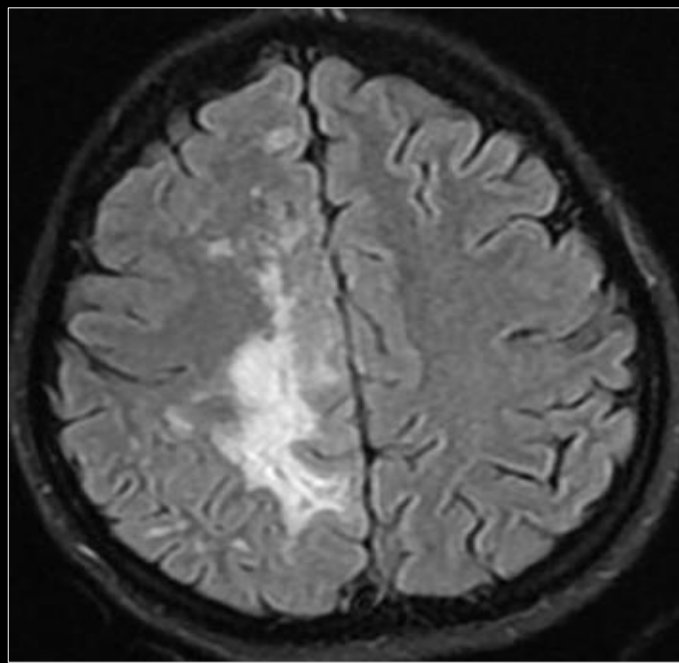
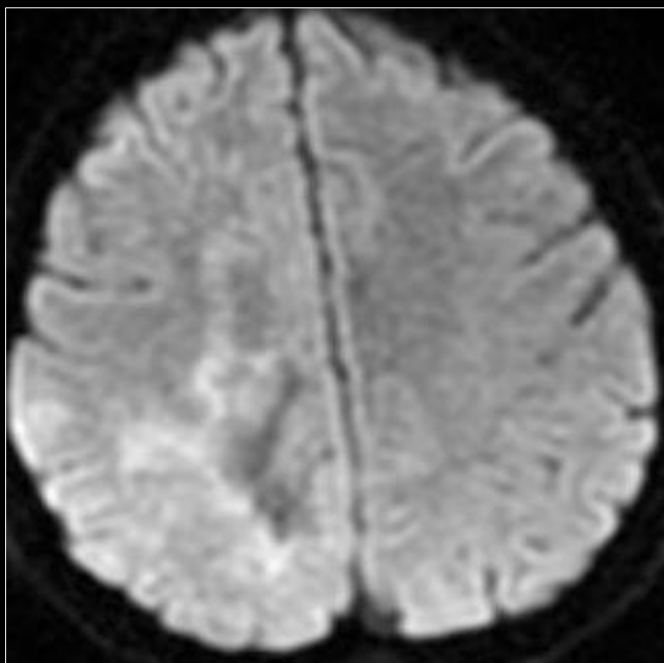


- Progresif Multifokal Lökoensefalopati
- JC Virüs
- Oligodendrositlerin hasarı
- Fokal demyelinizasyon
- Kitle etkisi az, periferal kısıtlanma
- Kontrastlanma yok
- T2/FLAIR uyumsuzluđu
- Samanyolu işareti

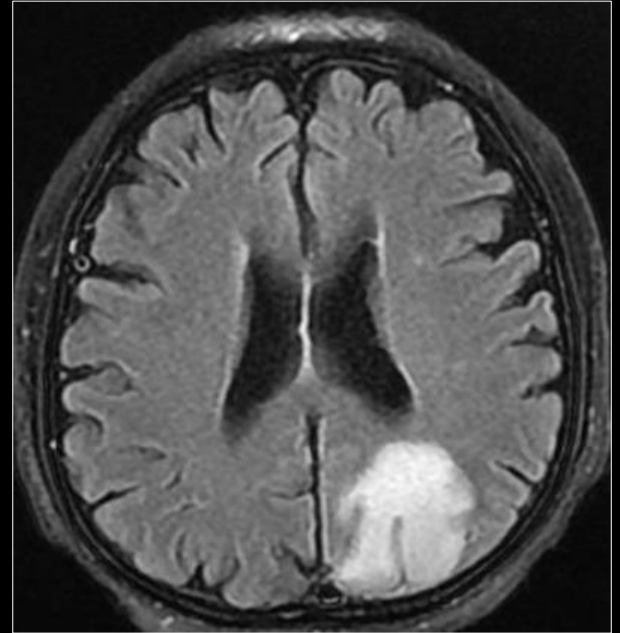
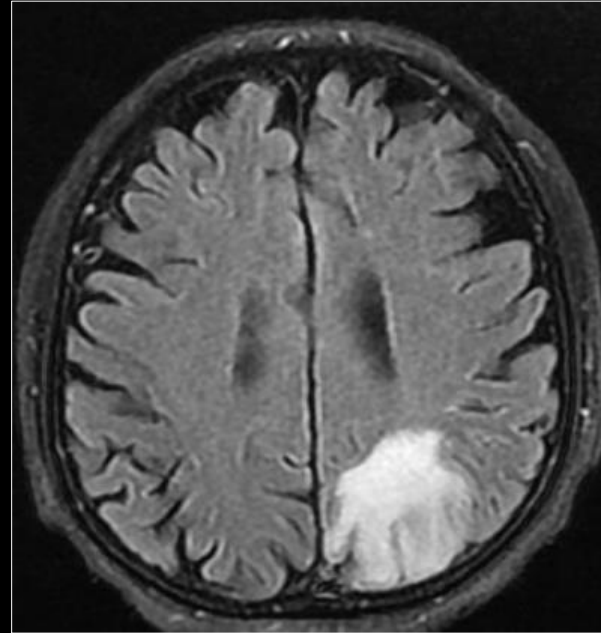
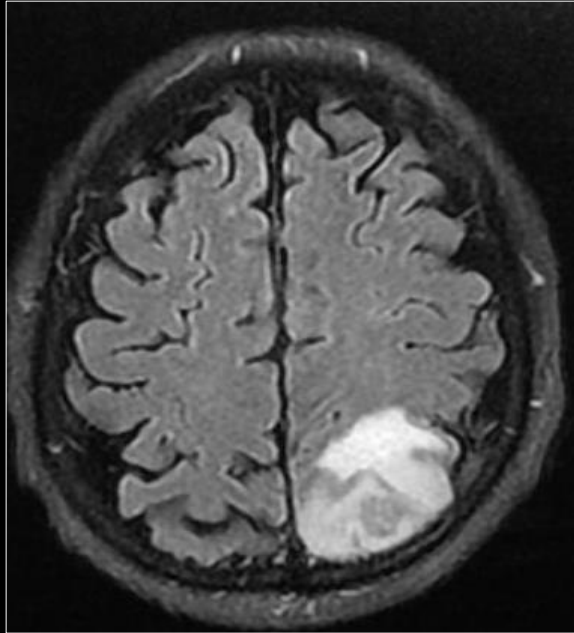
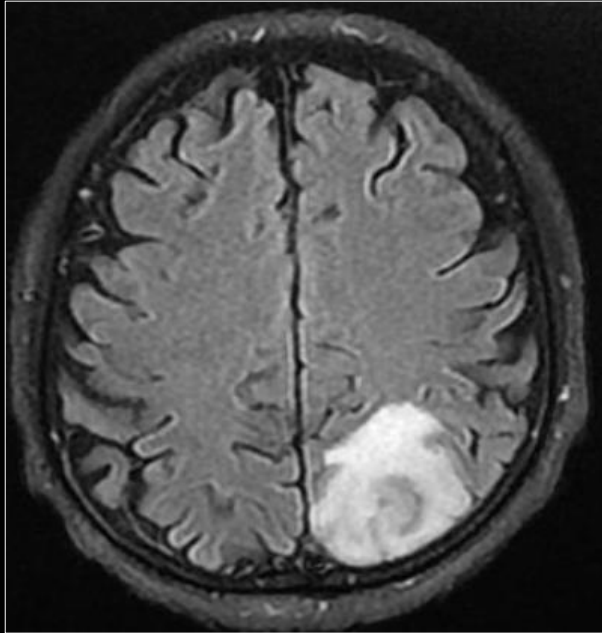
3. Progresif Multifokal L koensefalopati



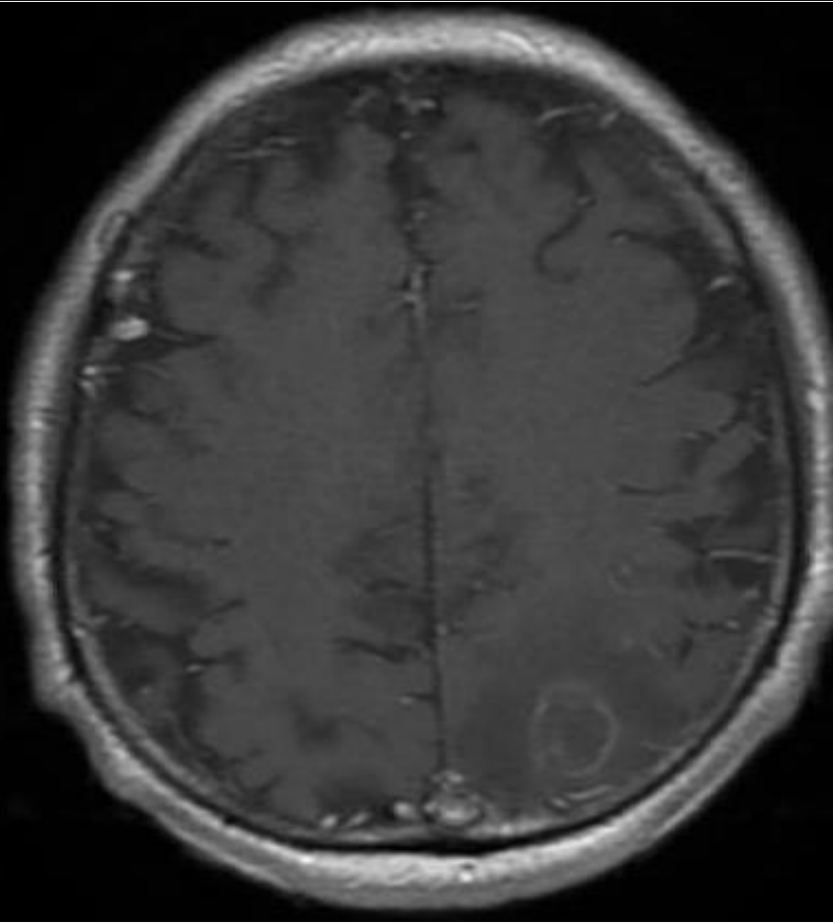
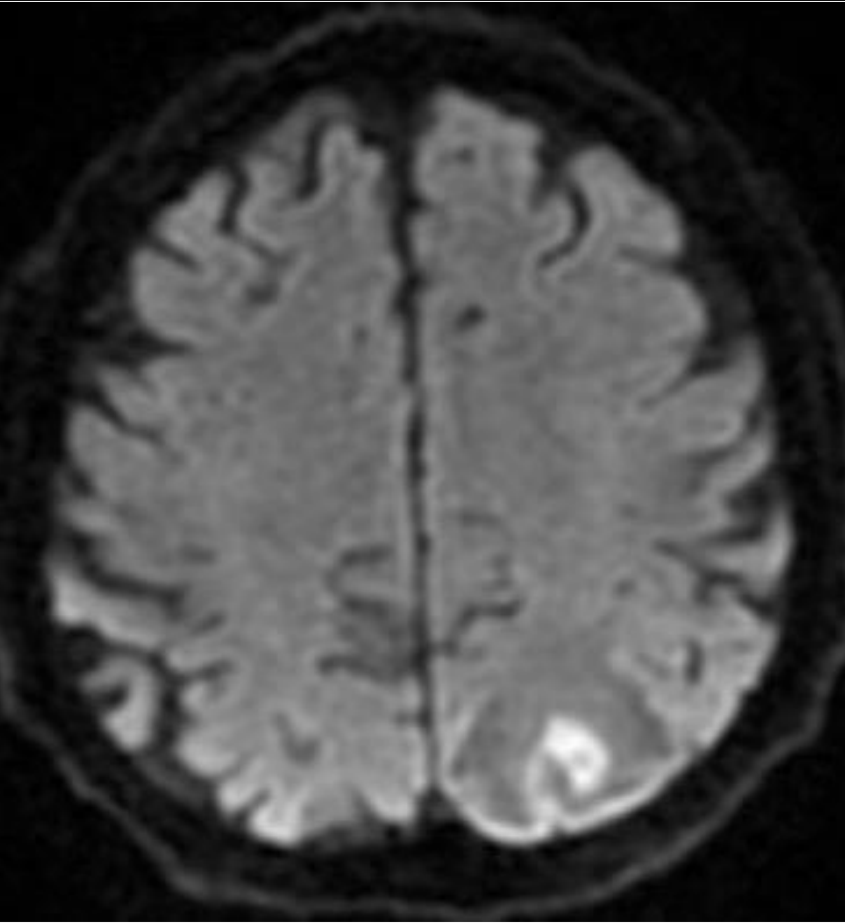
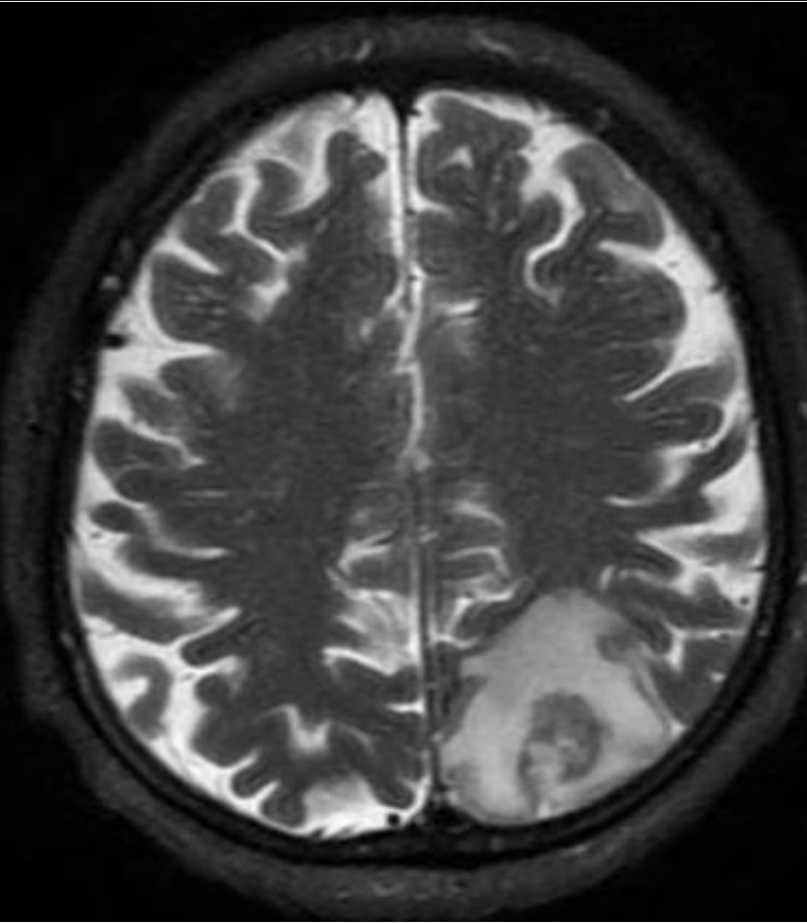
29 y k, postpartum d nemde ensefalopati bulguları

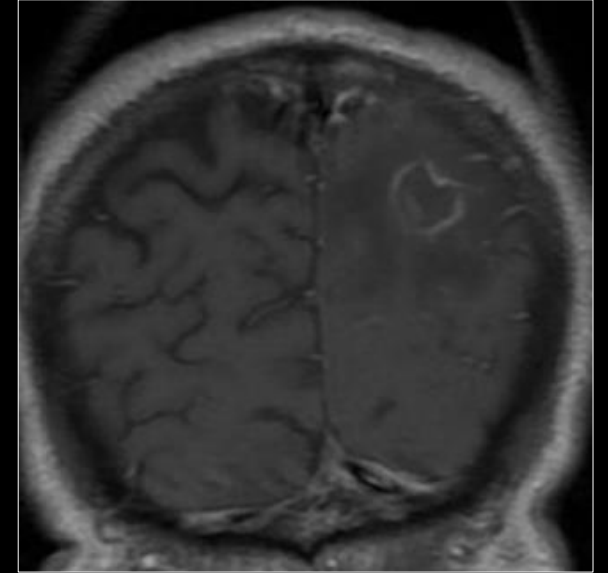
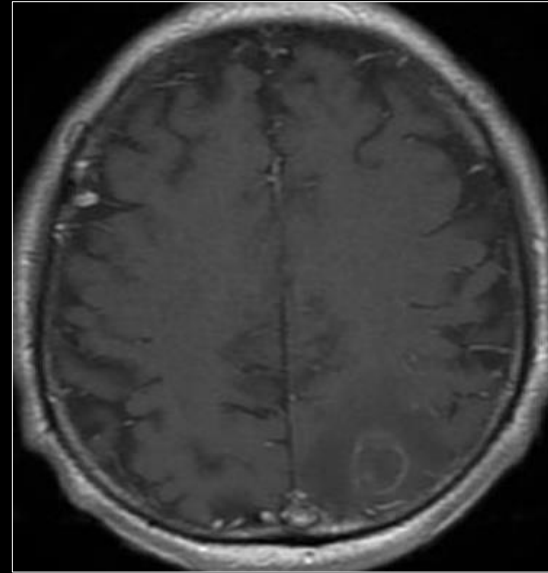
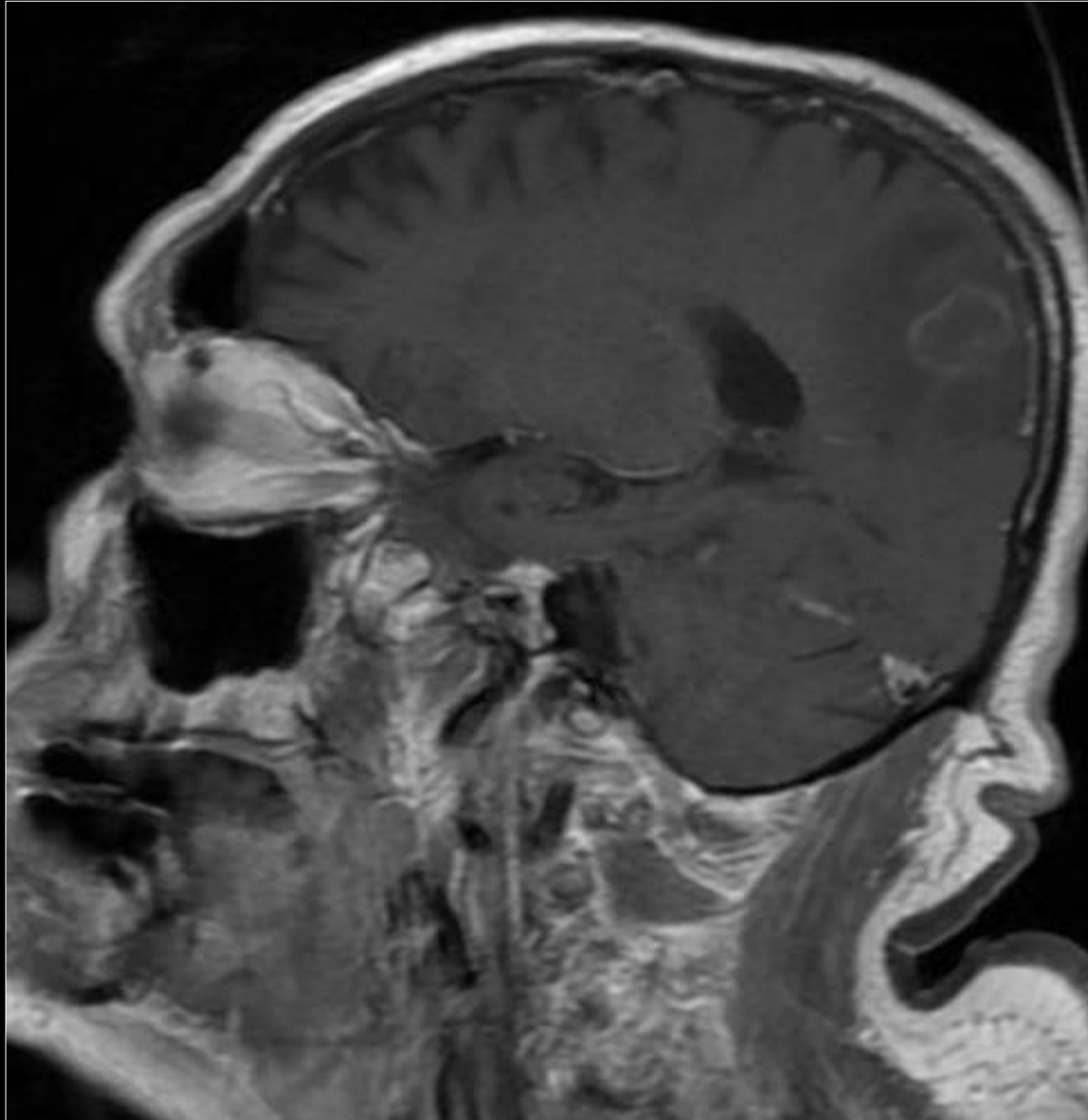


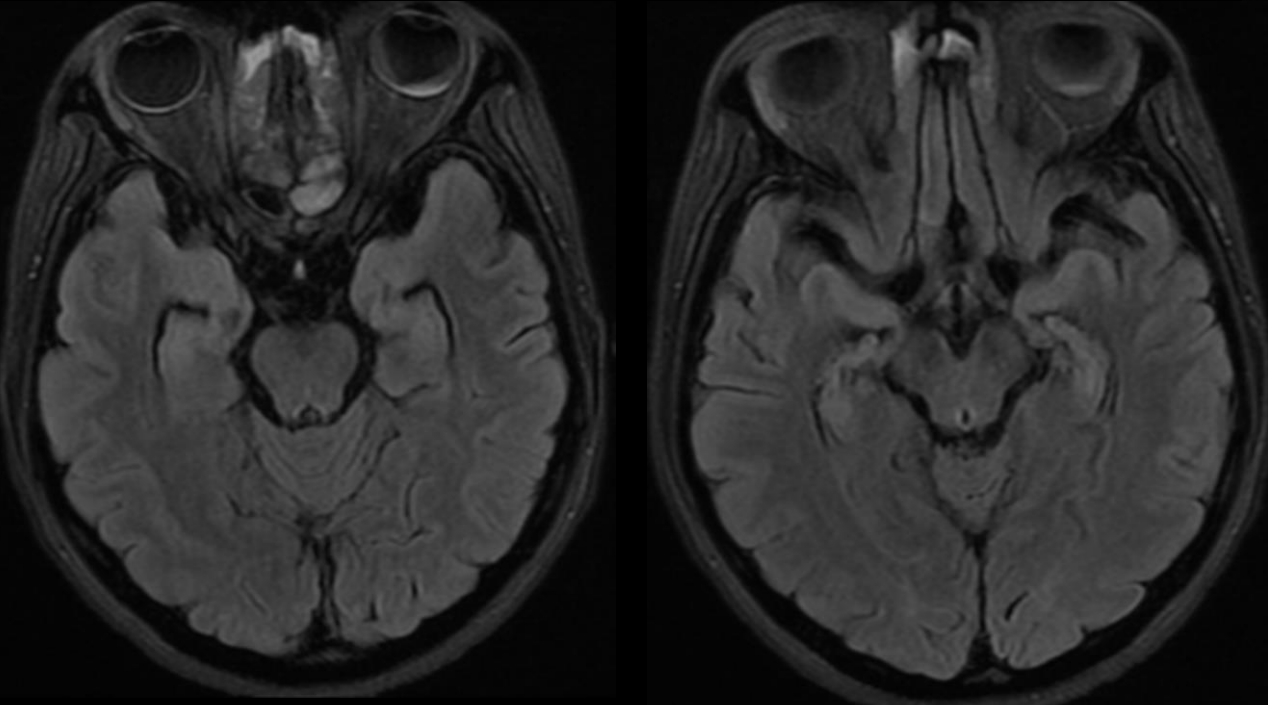
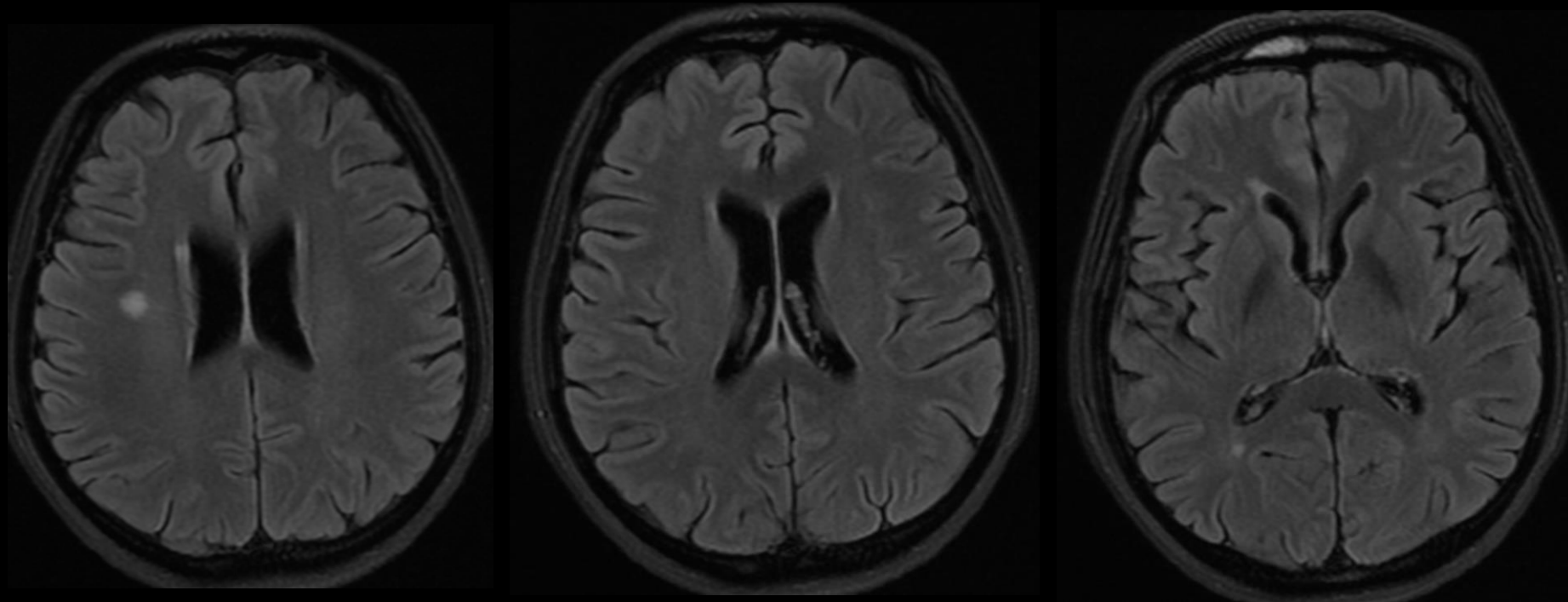
4.Kriptokok



68y e, HIV hastası

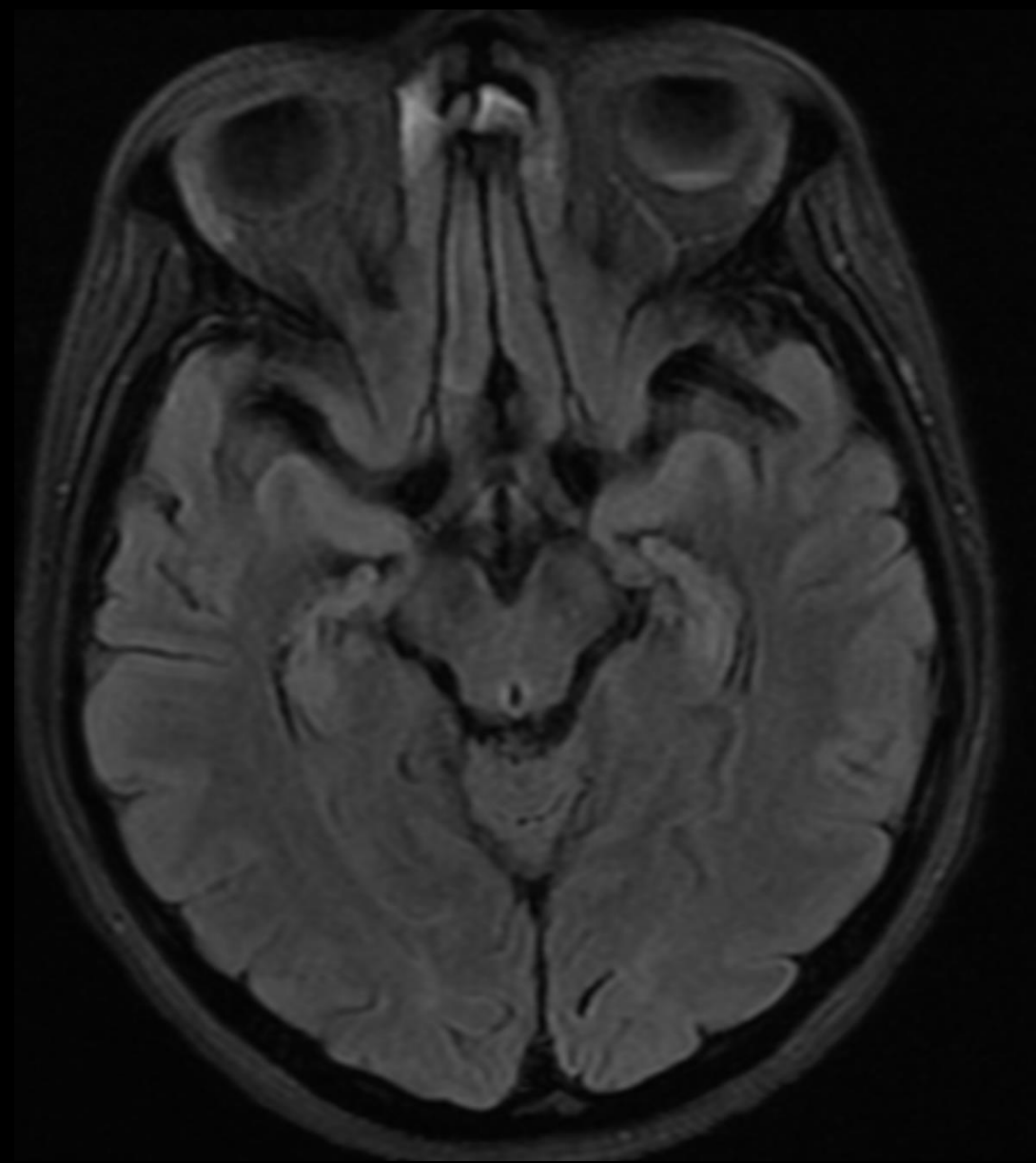
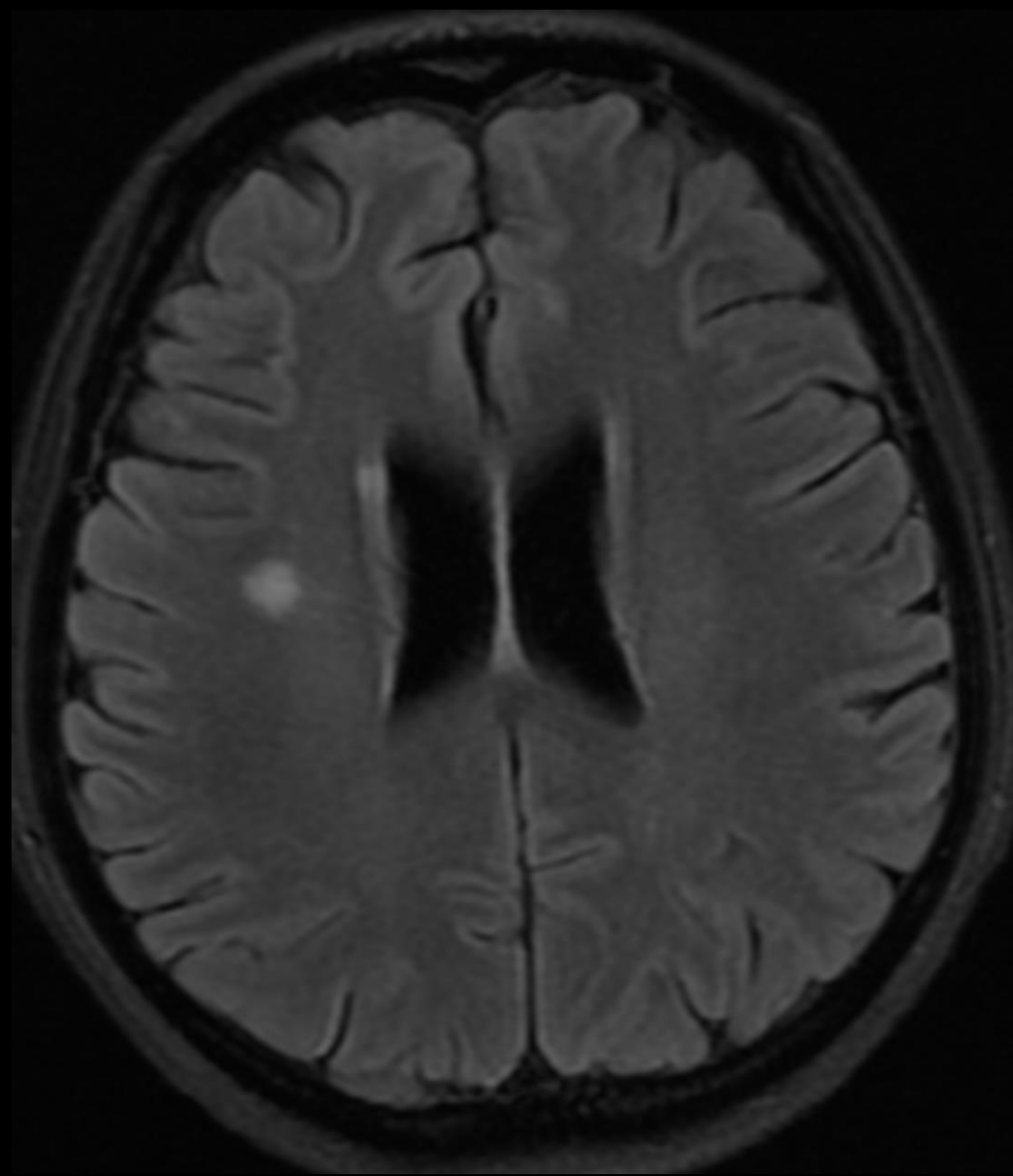


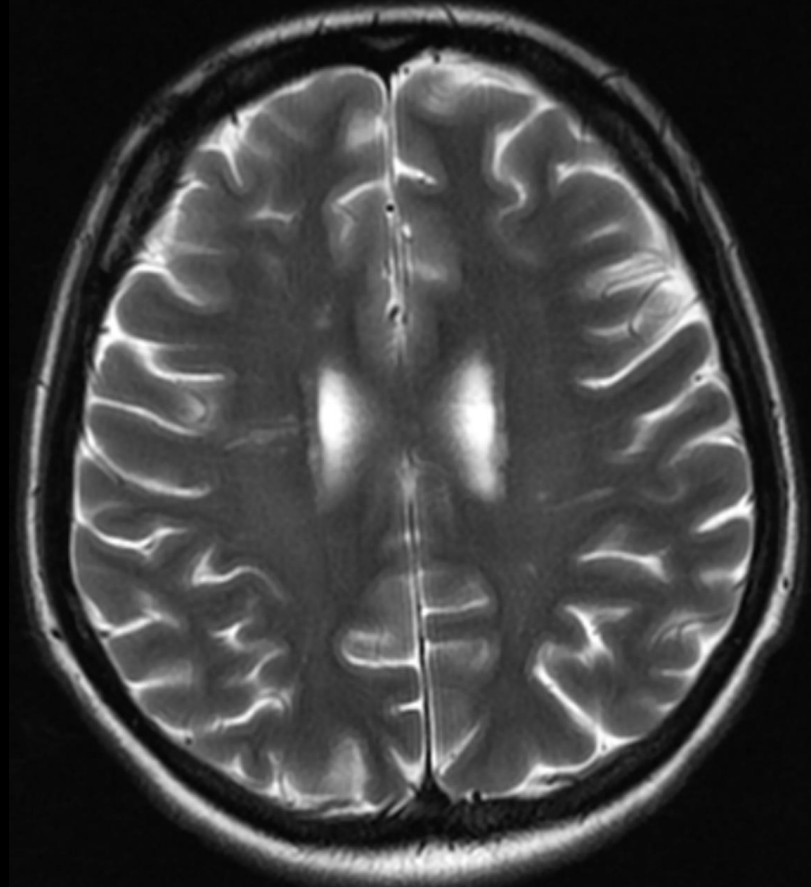
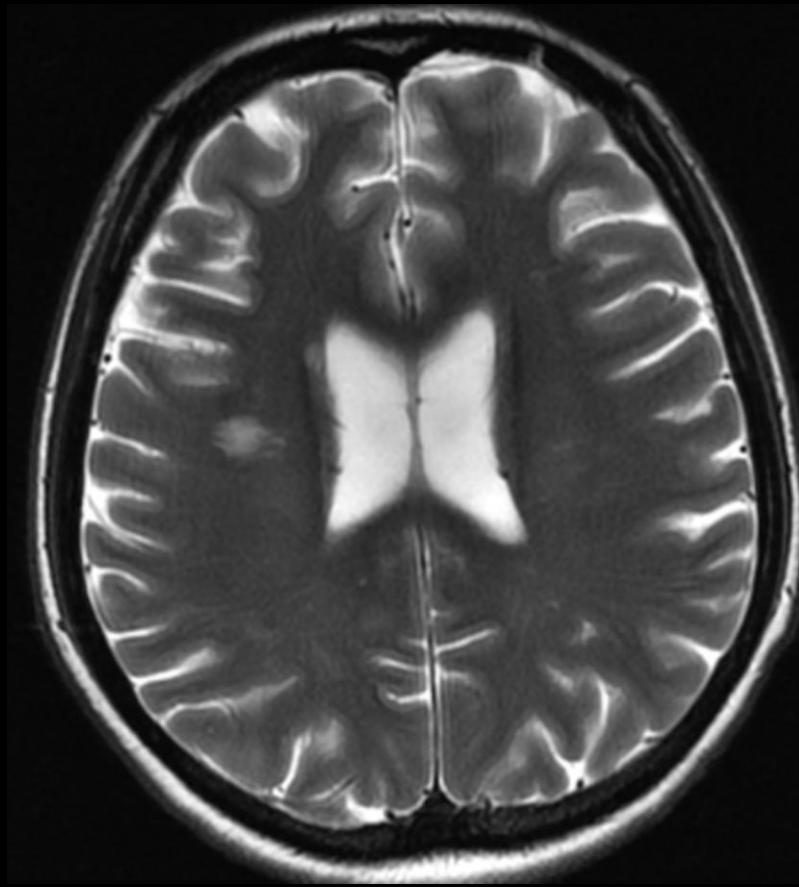
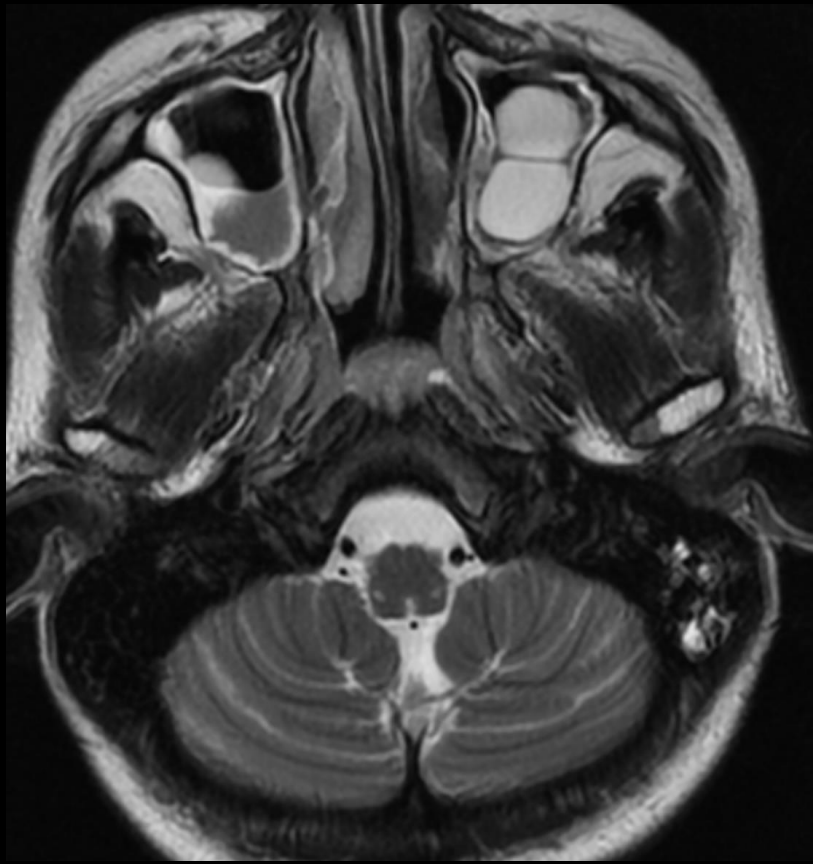


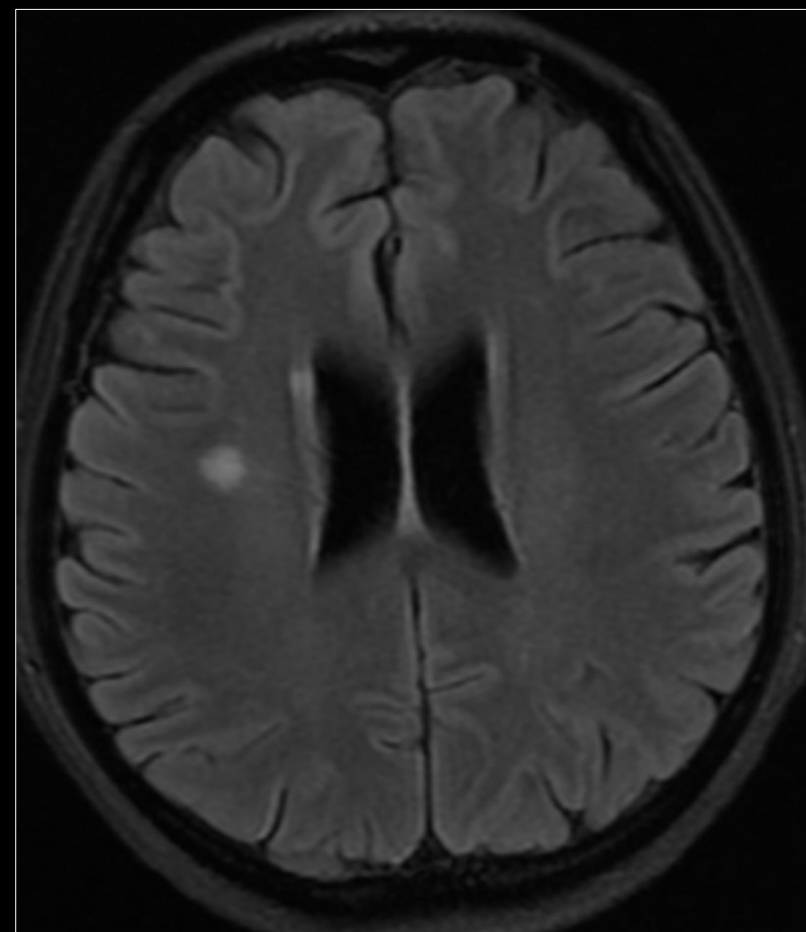
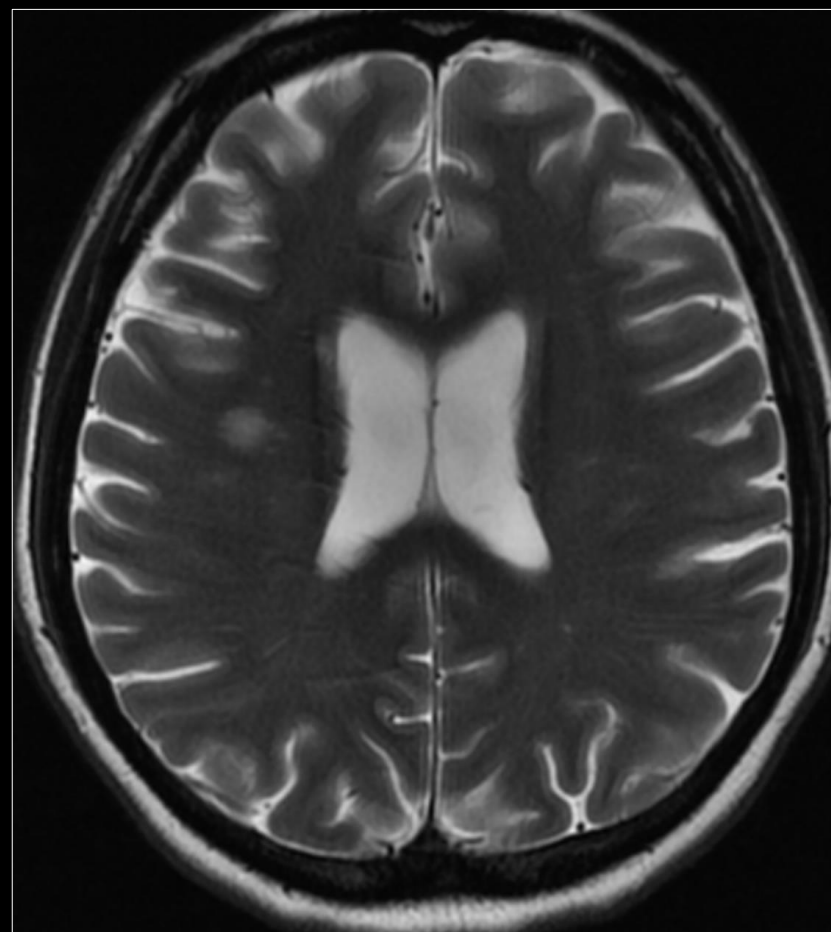
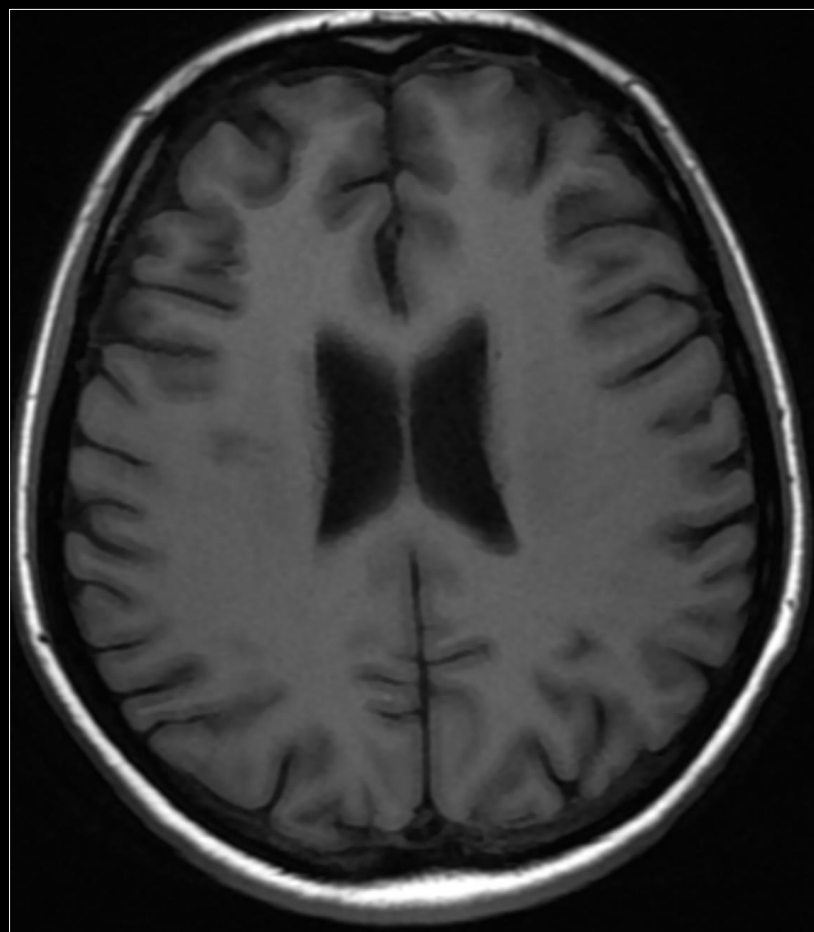


5.CMV

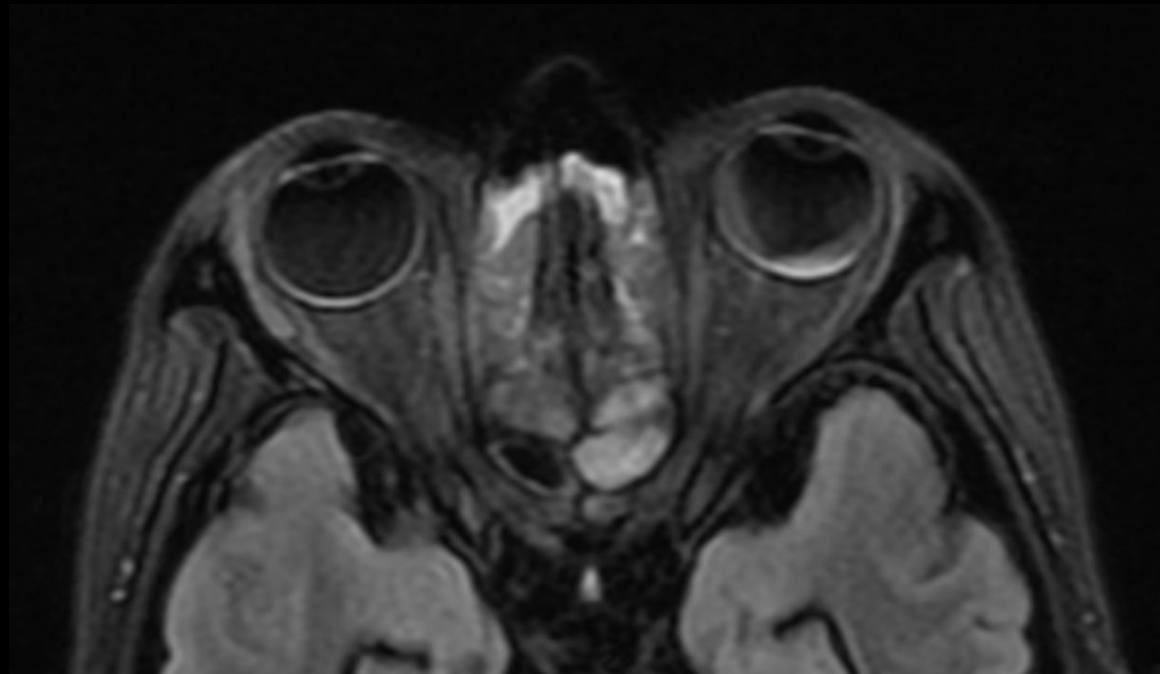
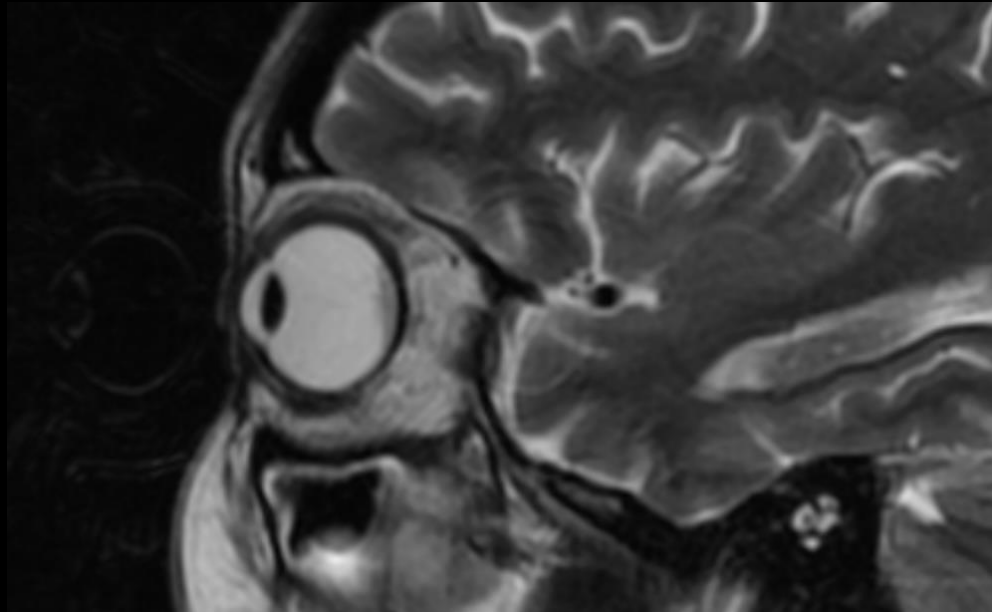
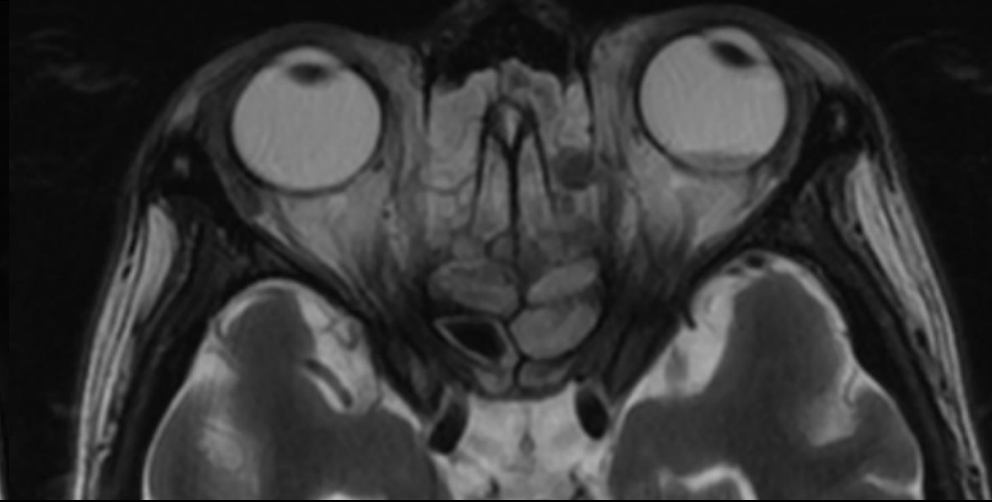
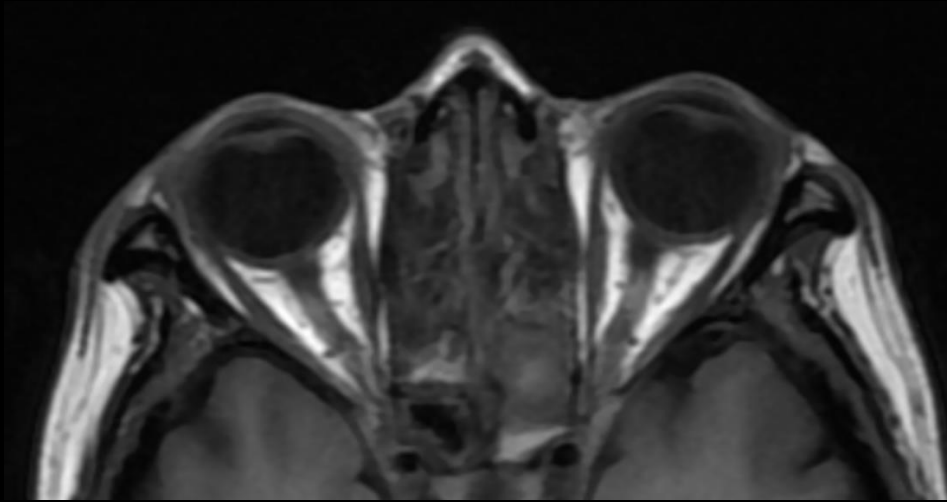
34y k, HIV hastası
Görme bulguları ile acil servise
başvuruyor



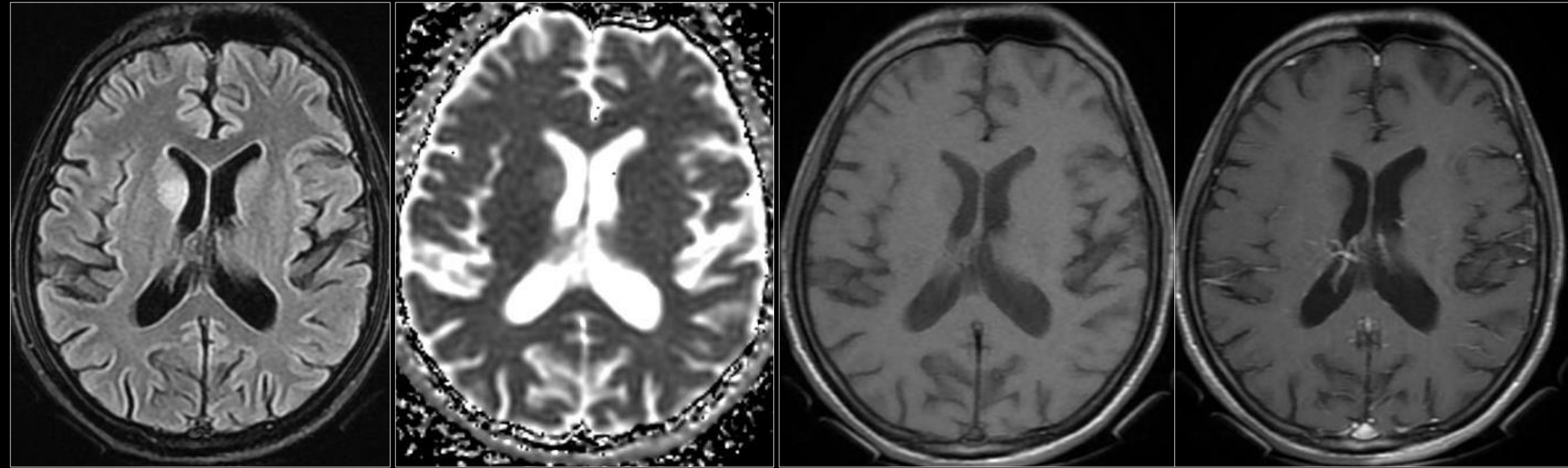




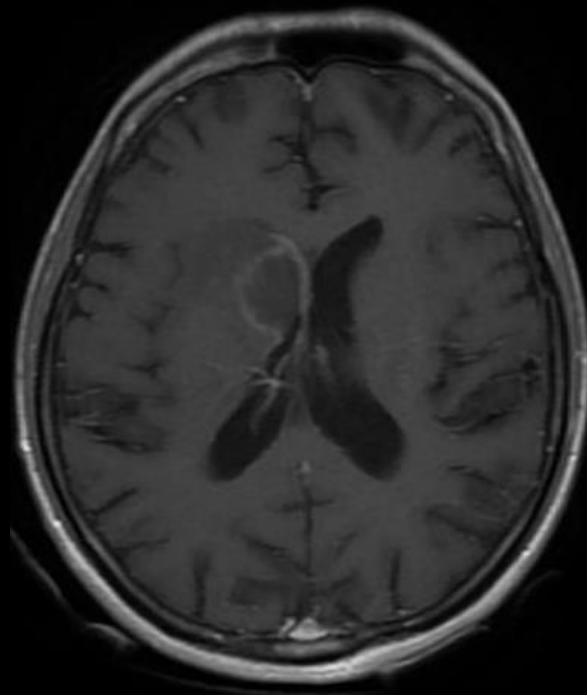
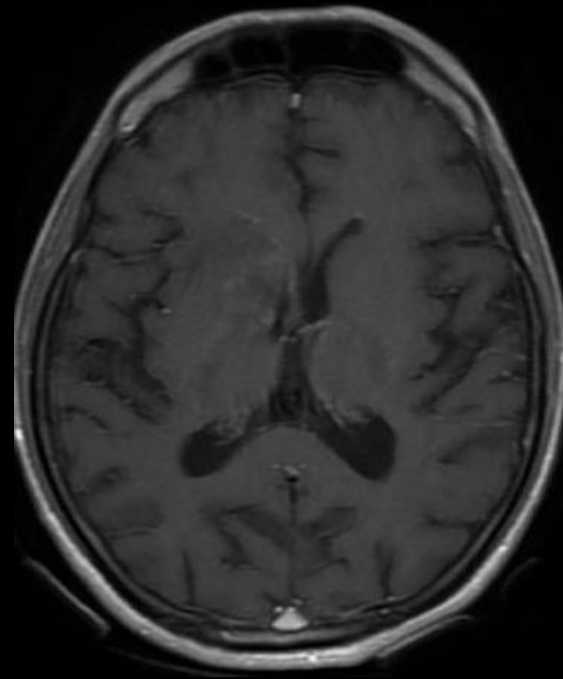
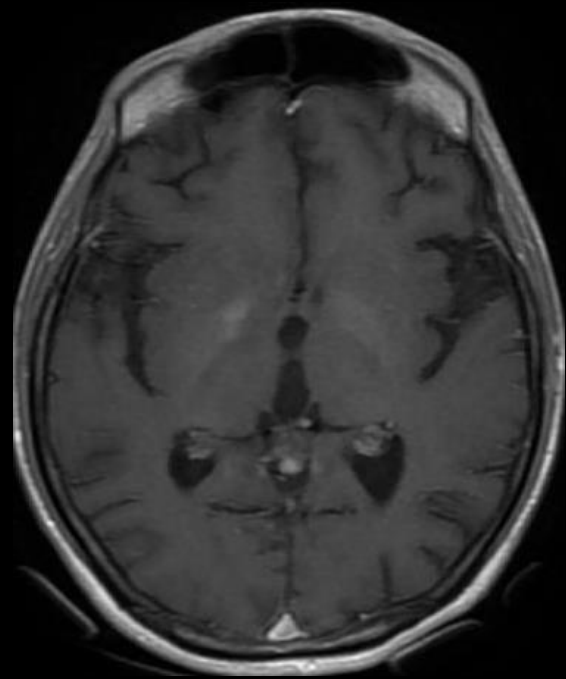
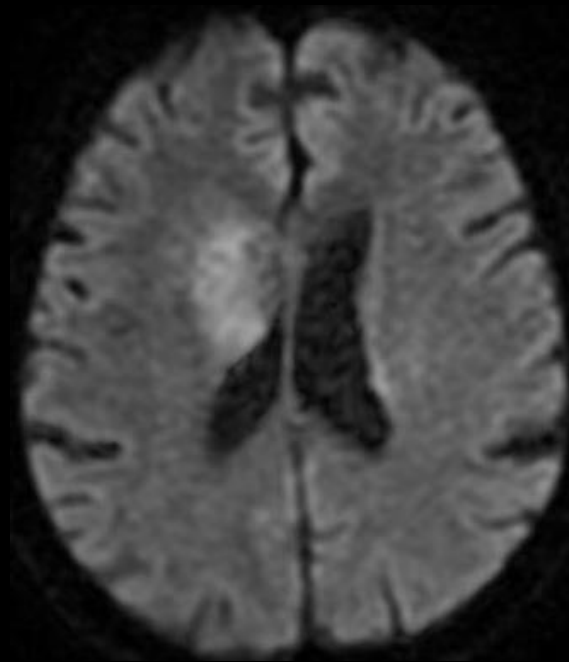
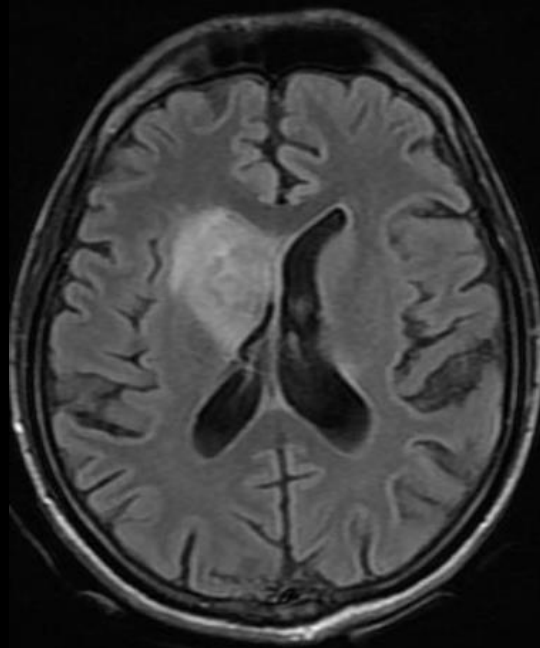
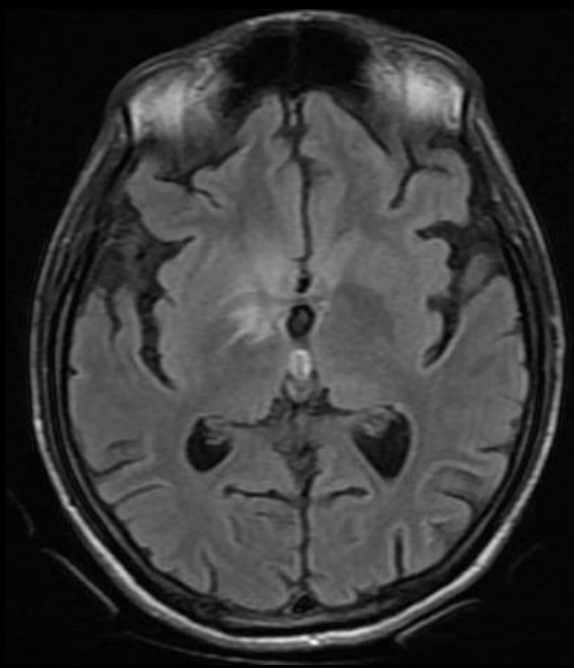
RETINAL DEKOLMAN

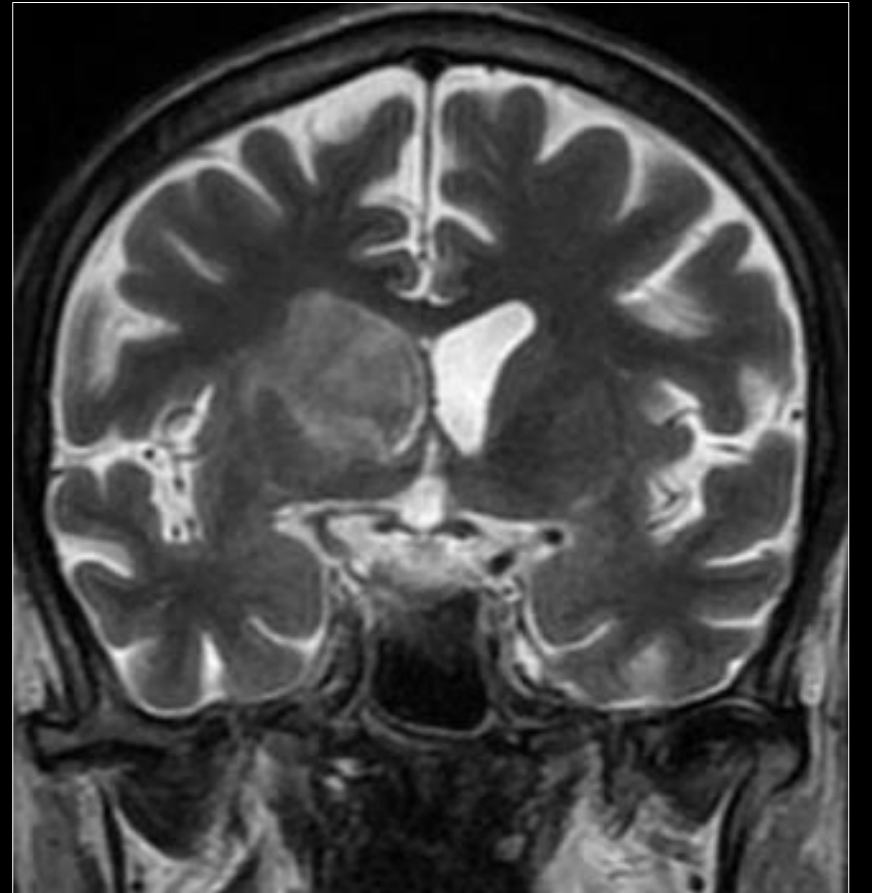
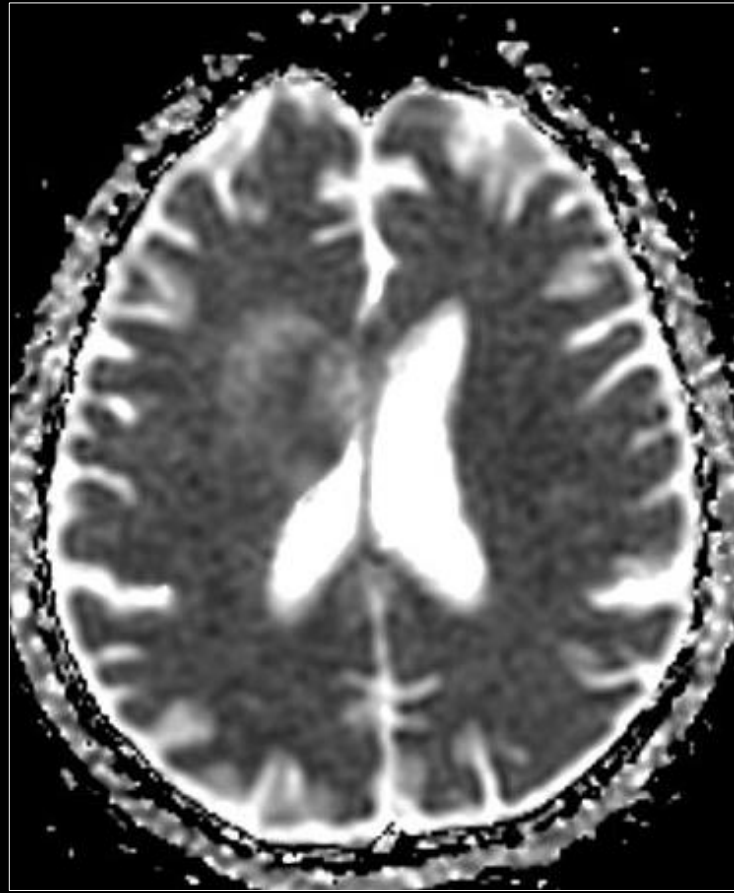
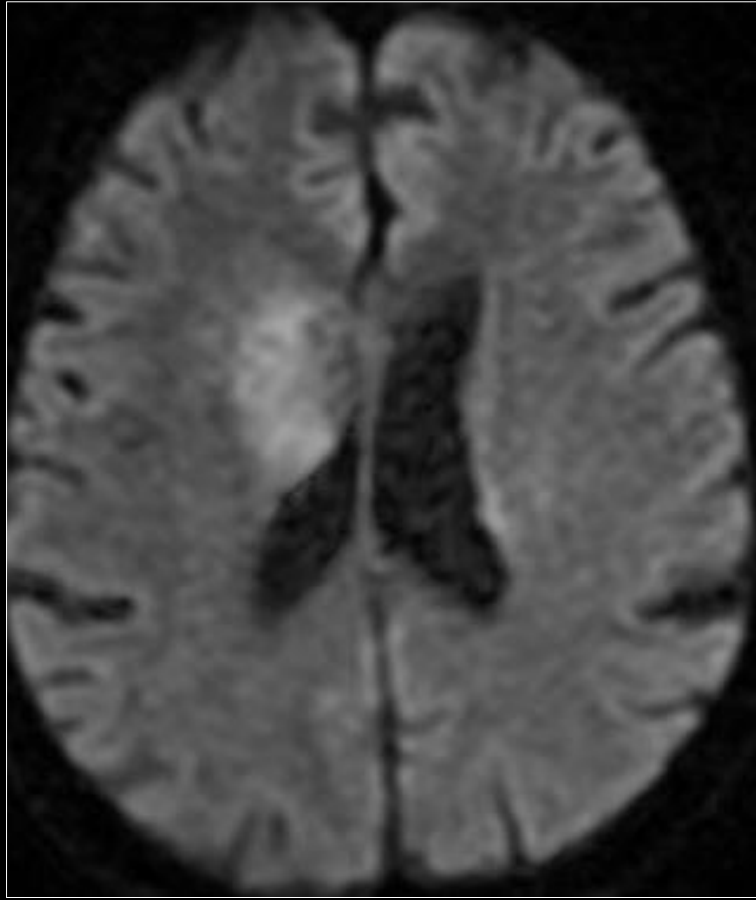


6. Lenfoma



34y e, HIV tanılı hasta



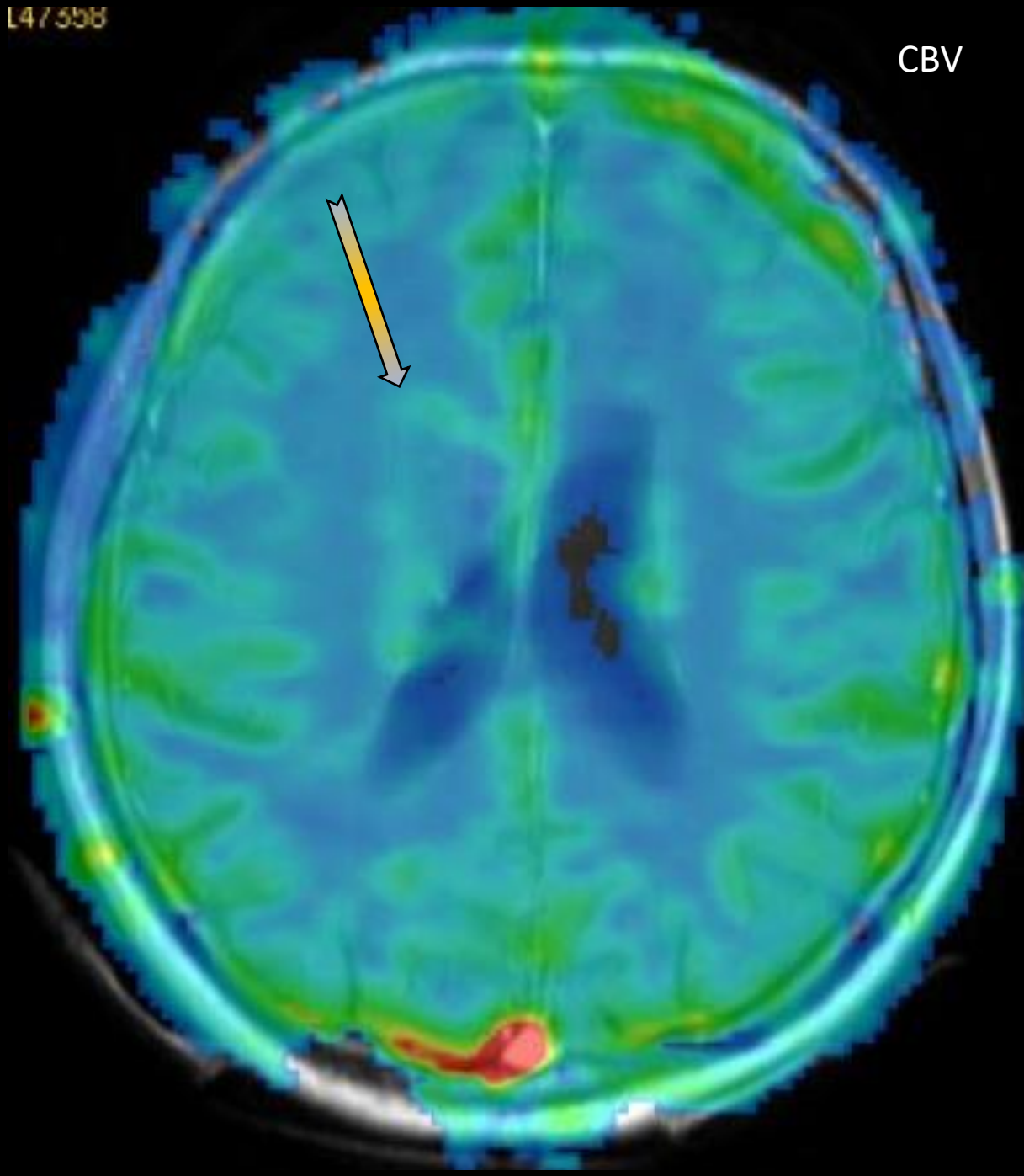
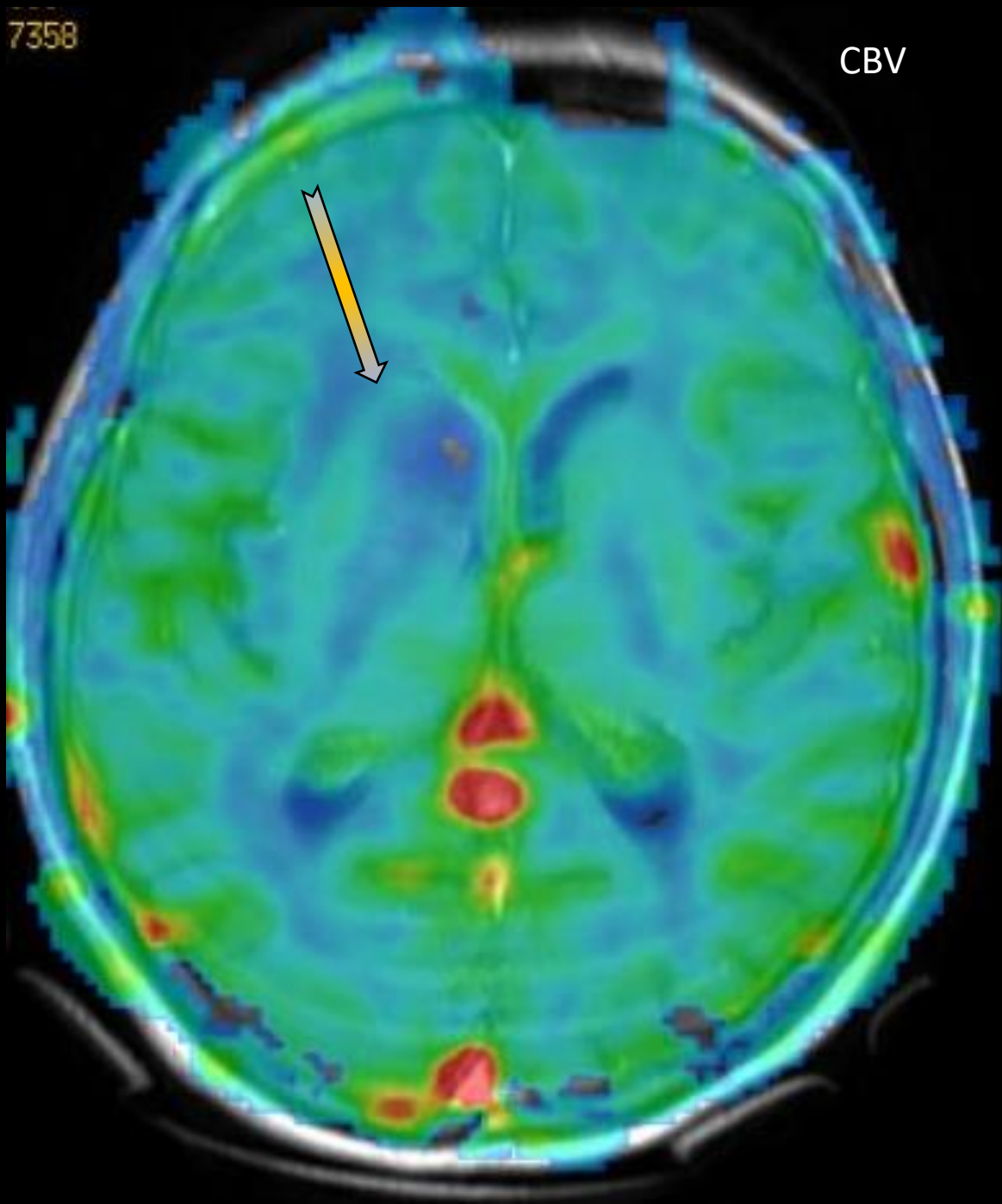


7358

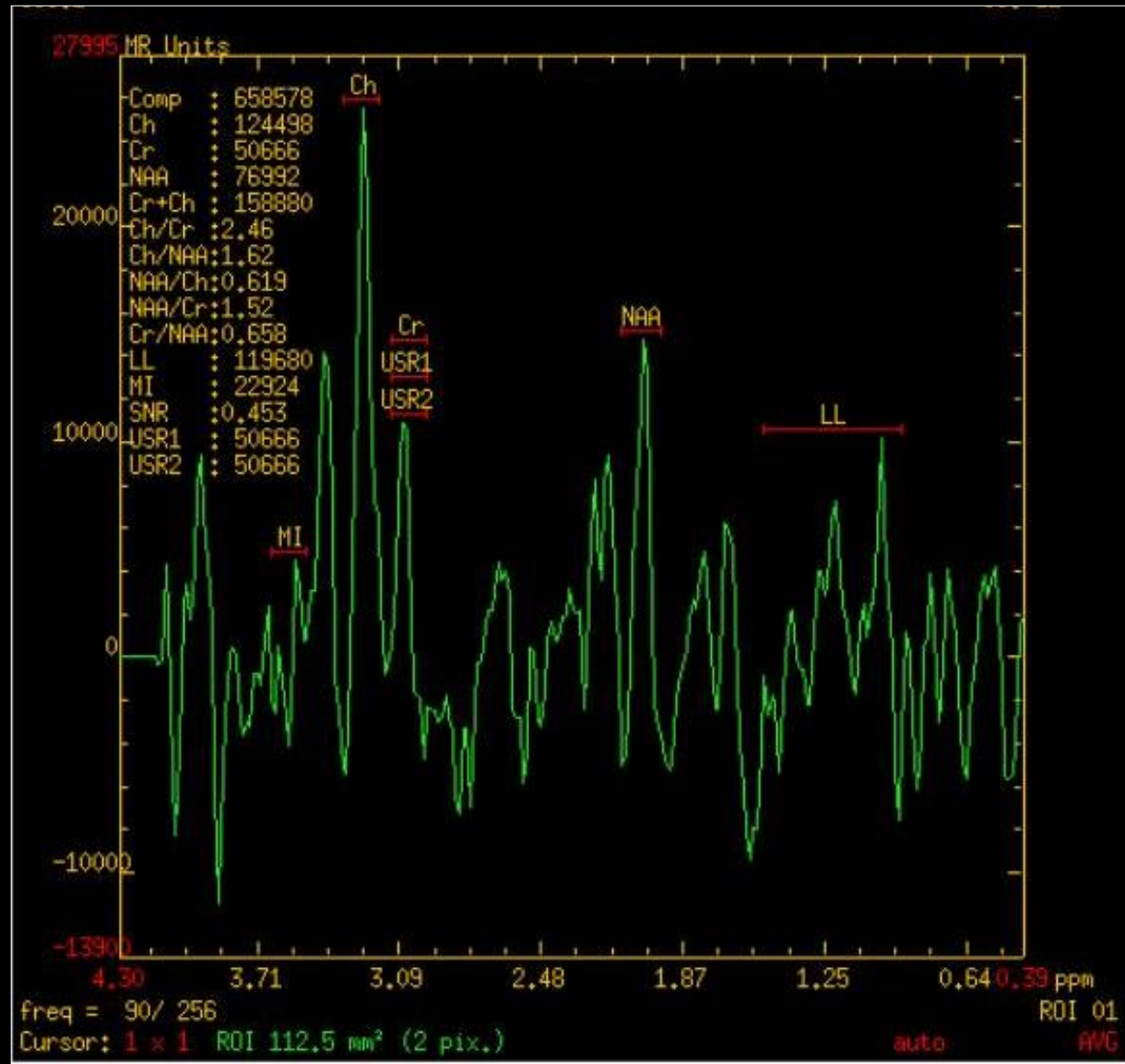
L47358

CBV

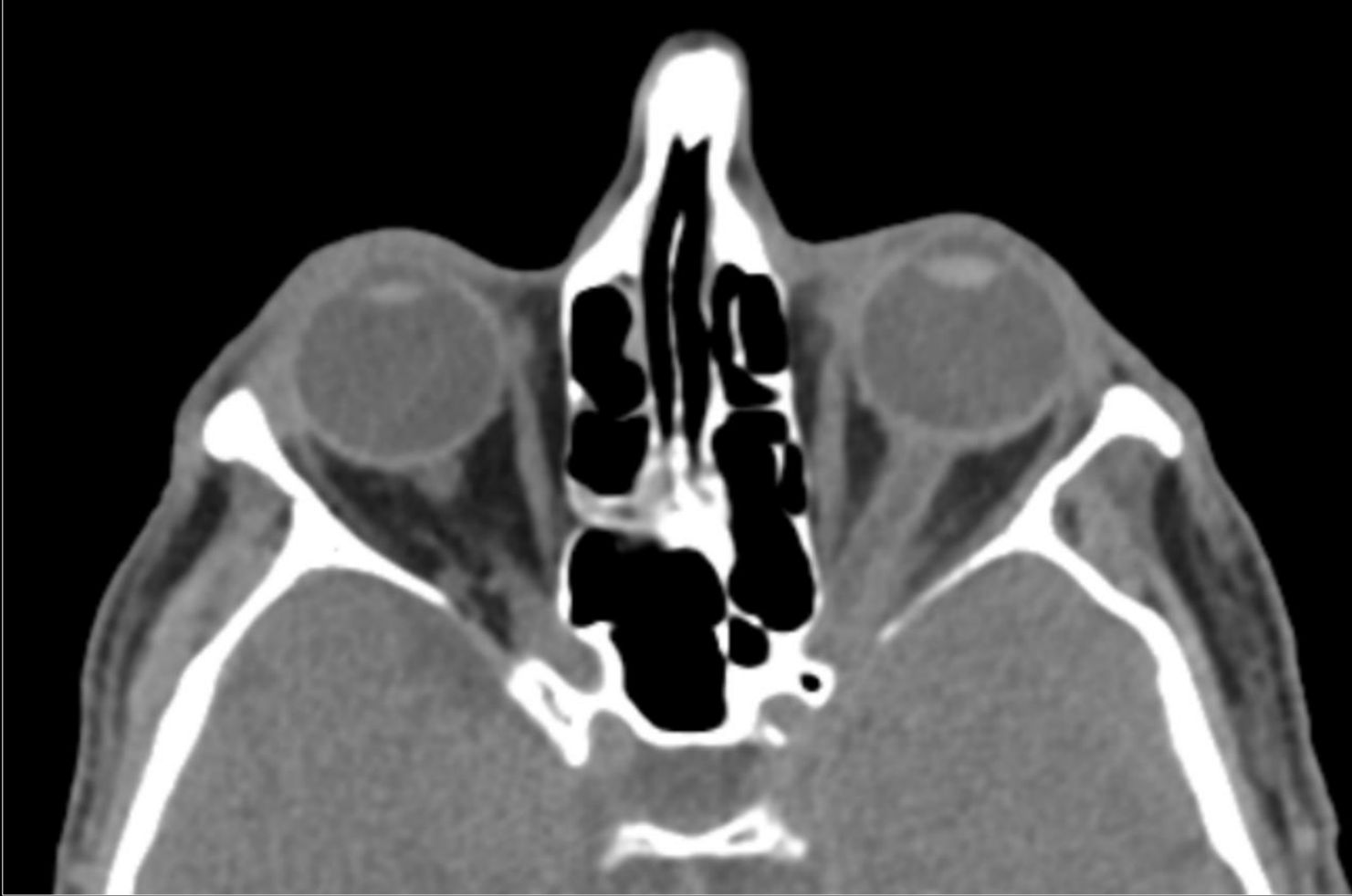CBV



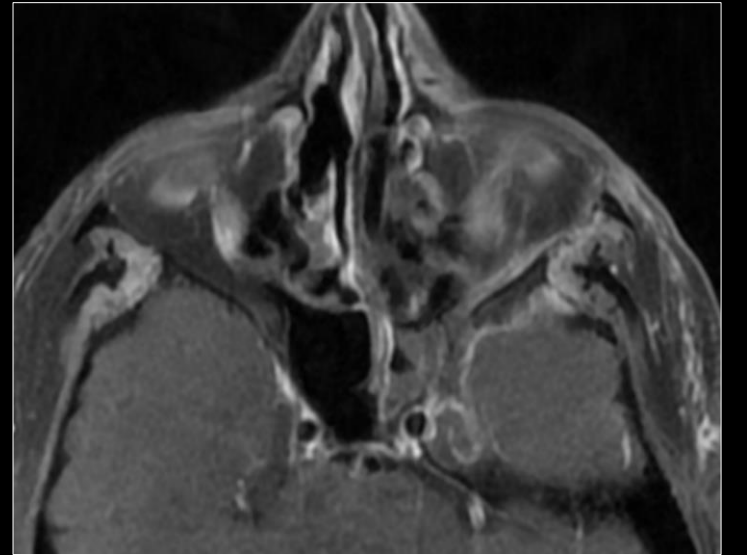
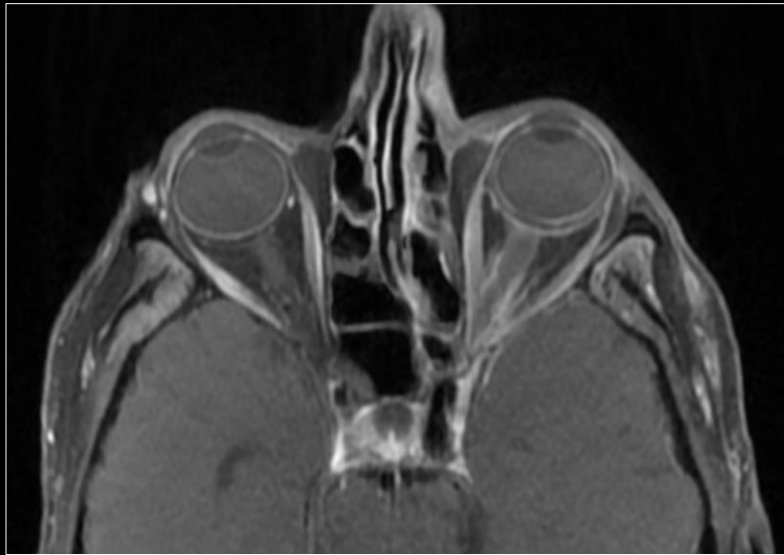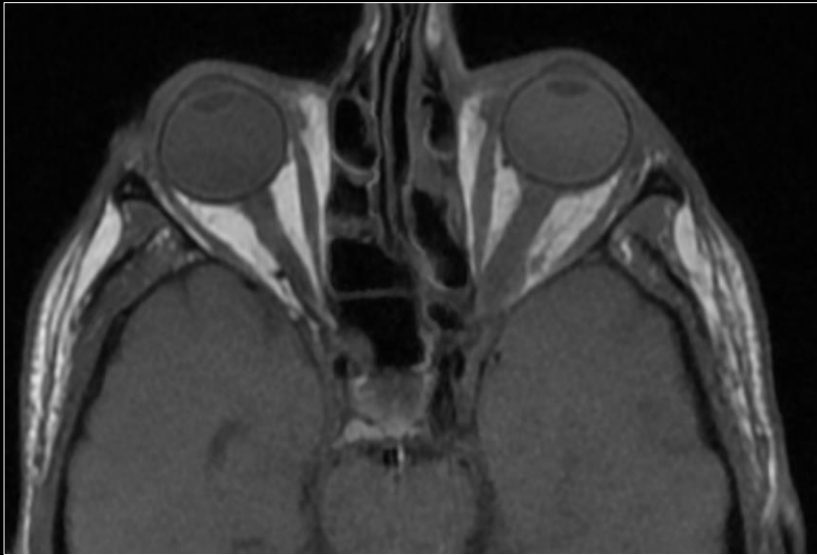
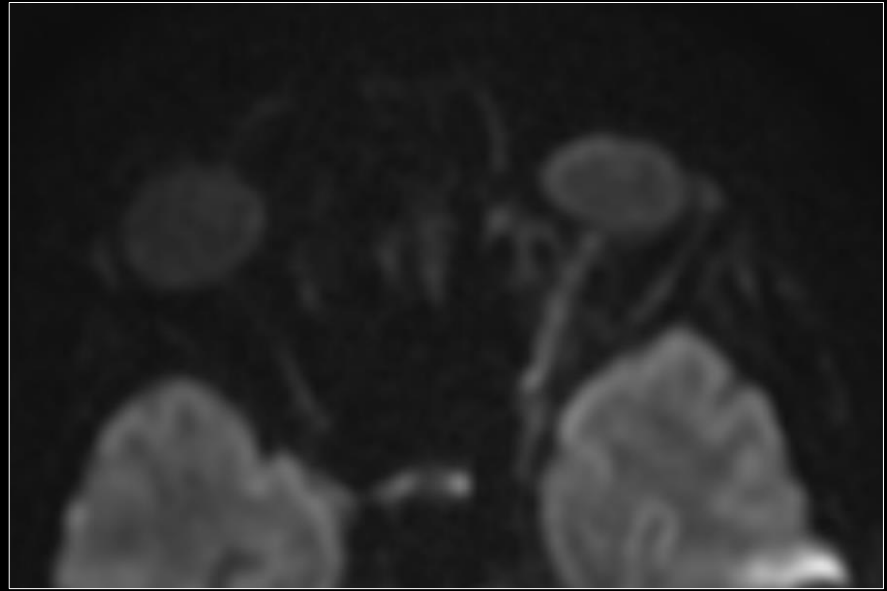
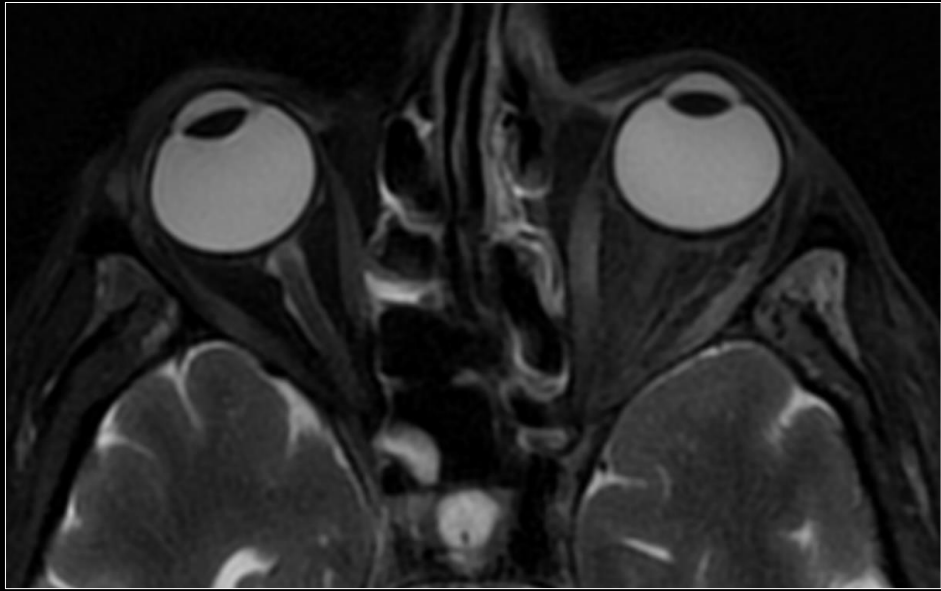
MR SPEKTROSKOPI

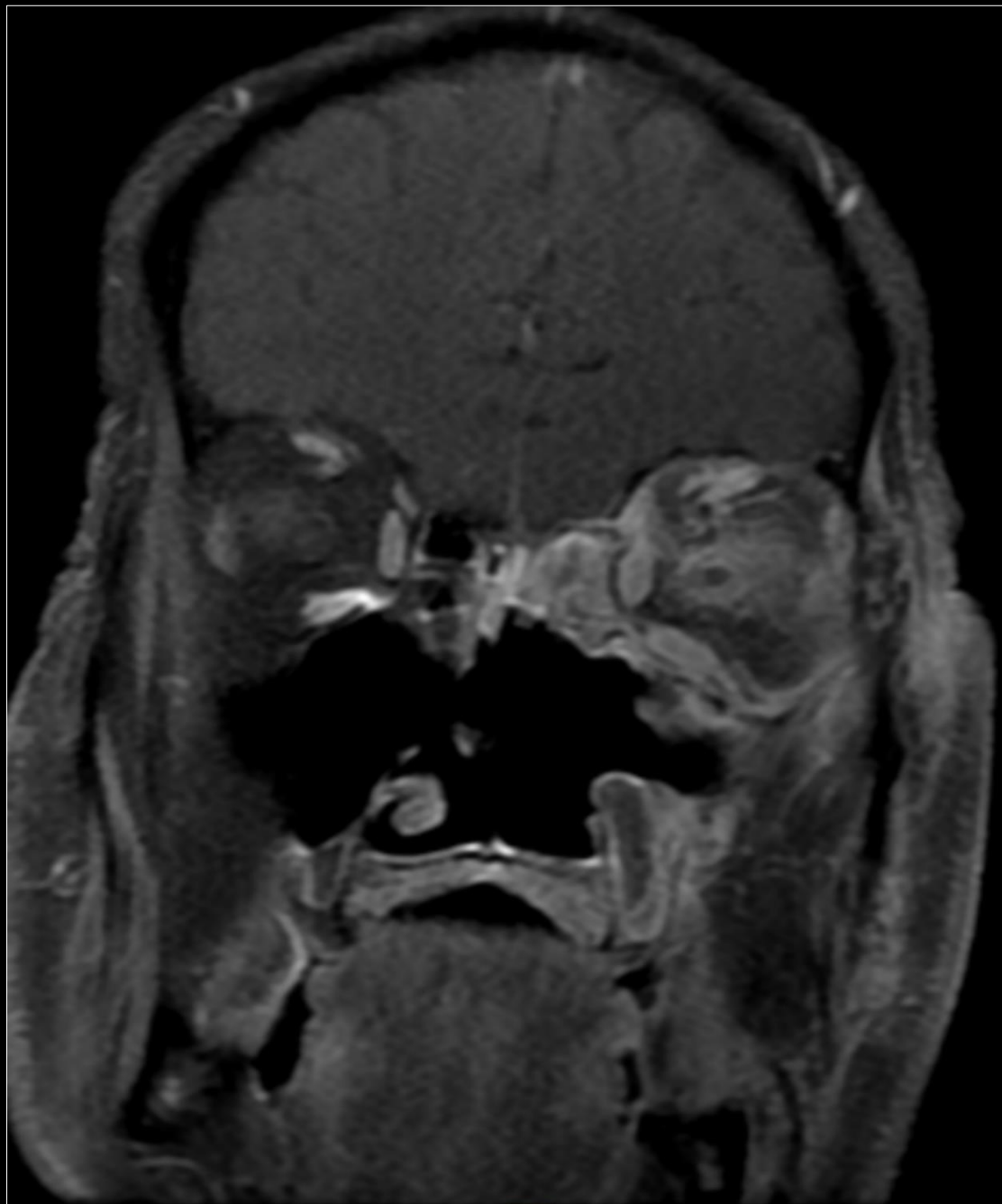


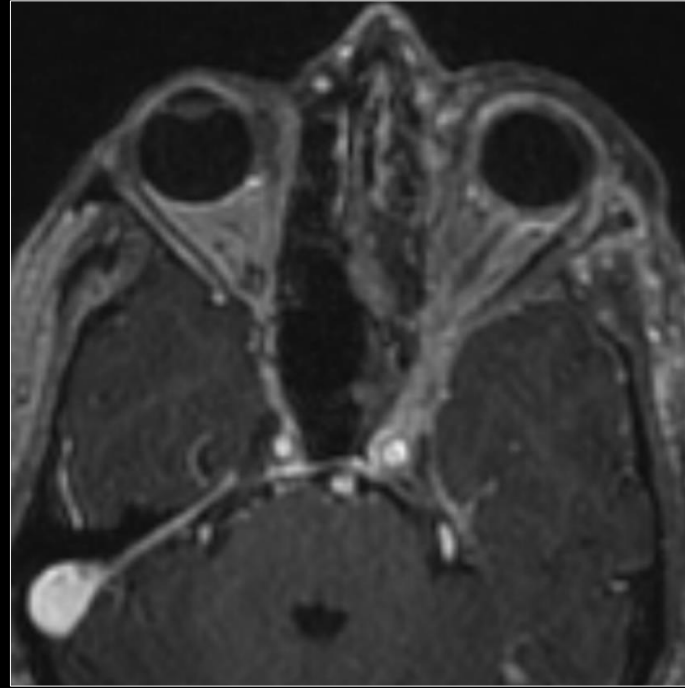
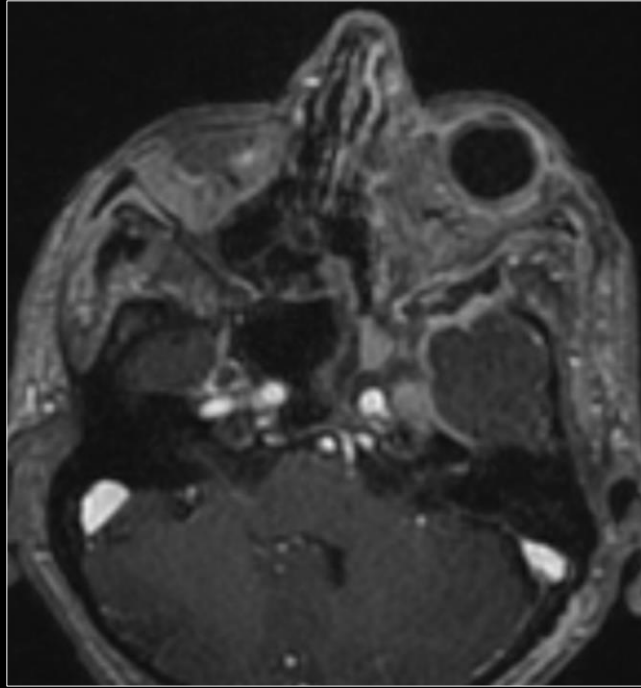
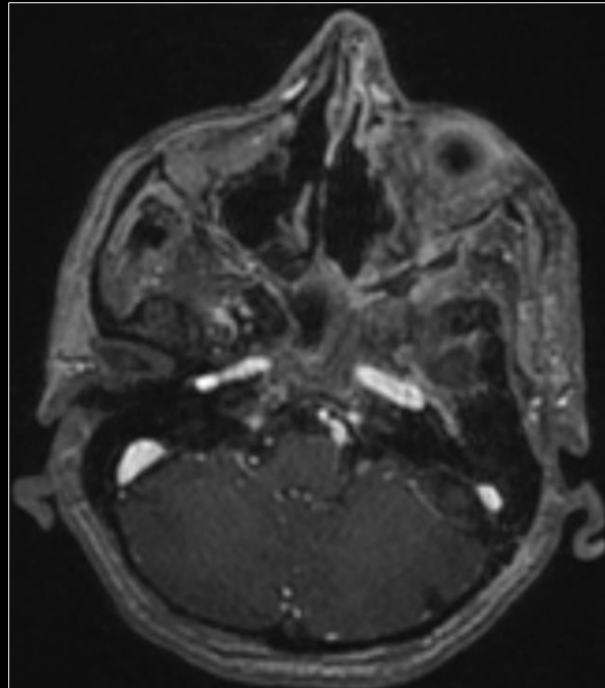
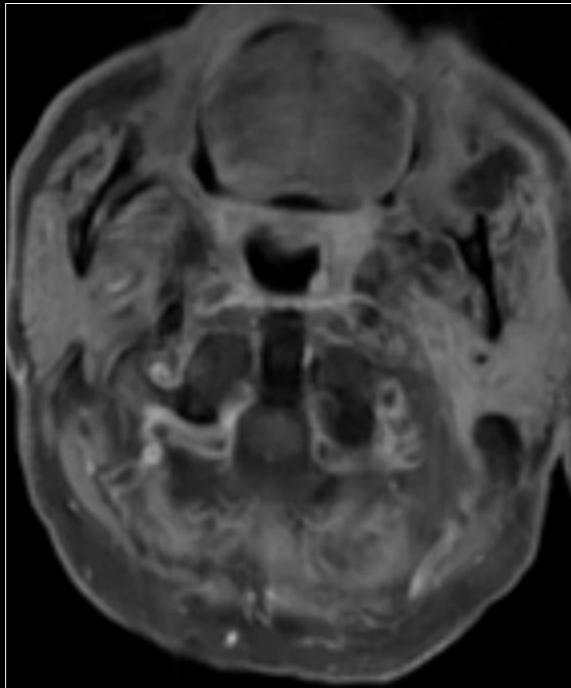
7.Aspergilloz



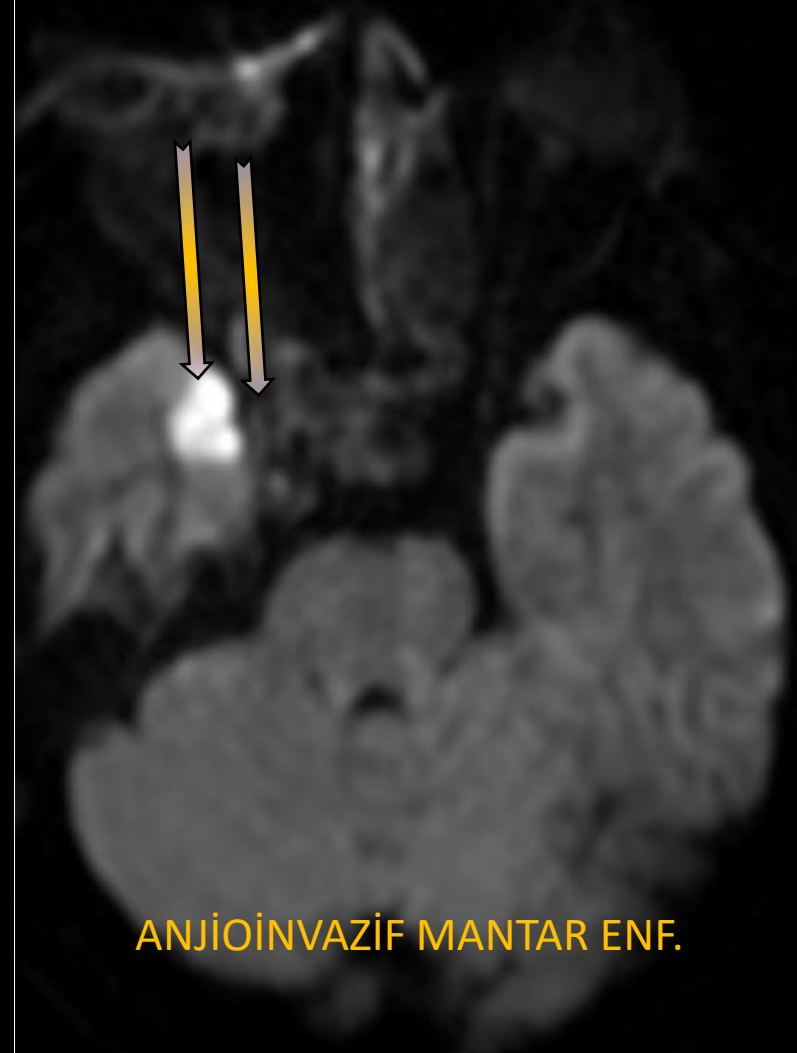
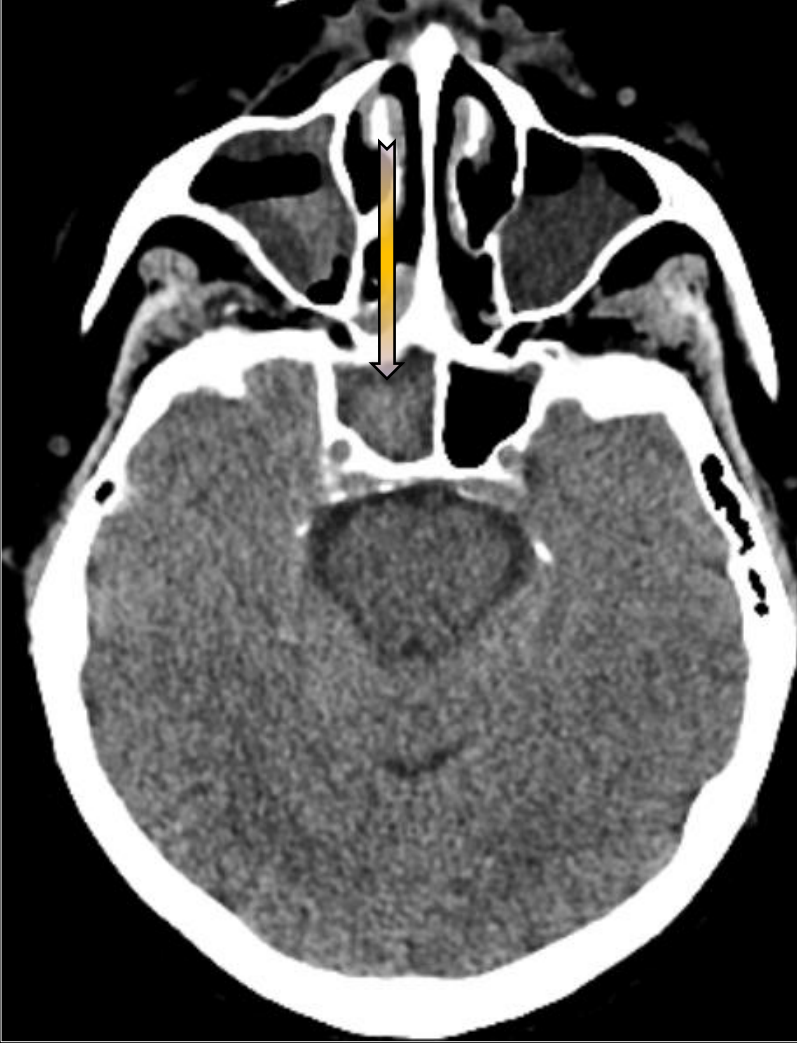63 y e, bulanık görme yakınmasıyla acil servise başvuruyor





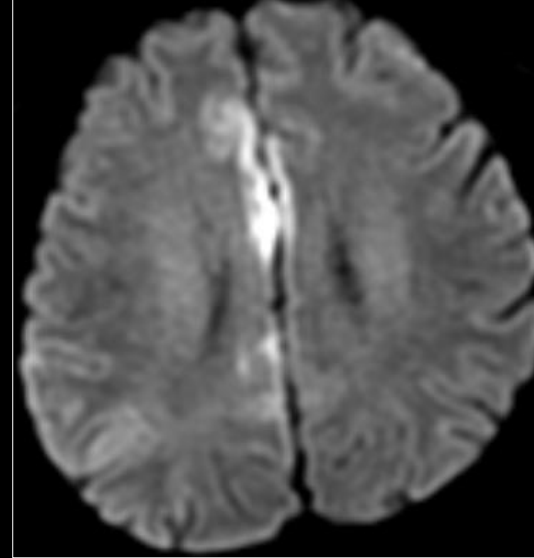
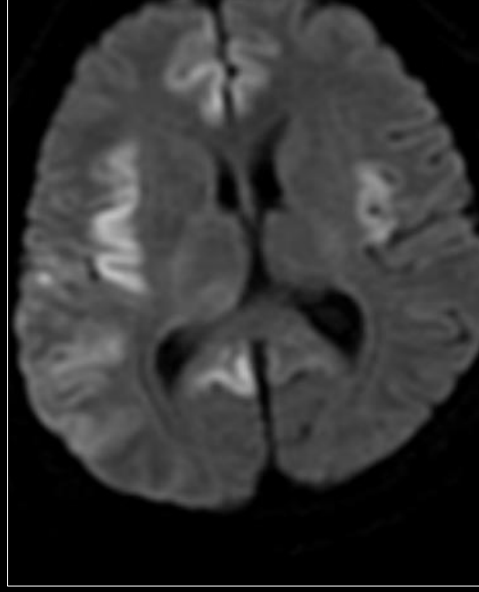
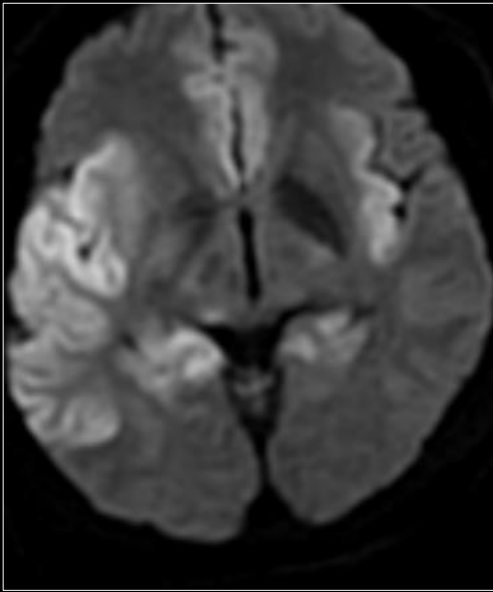
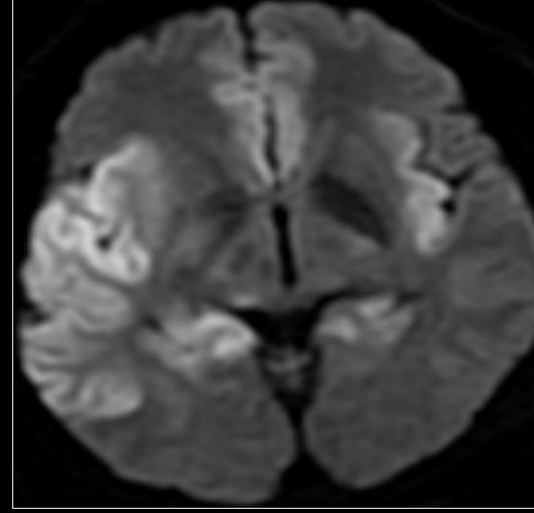
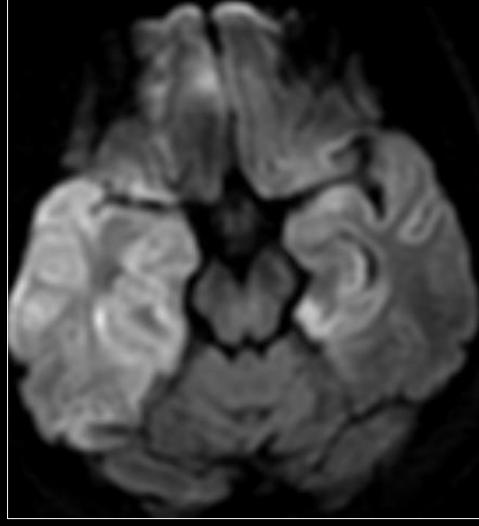
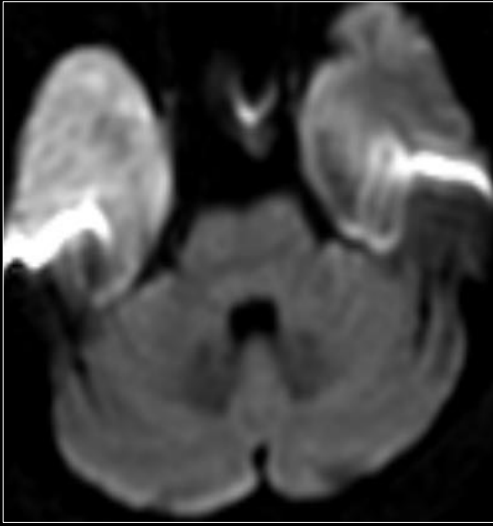


8.Mukormikozis



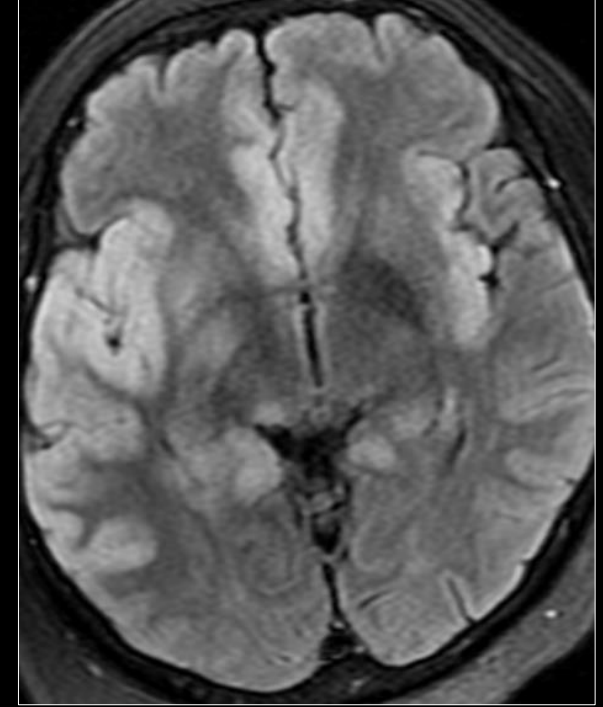
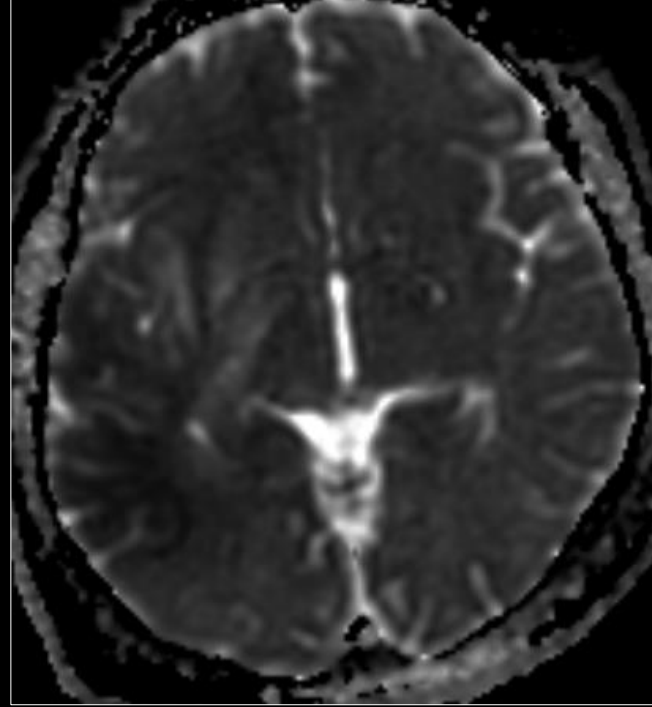
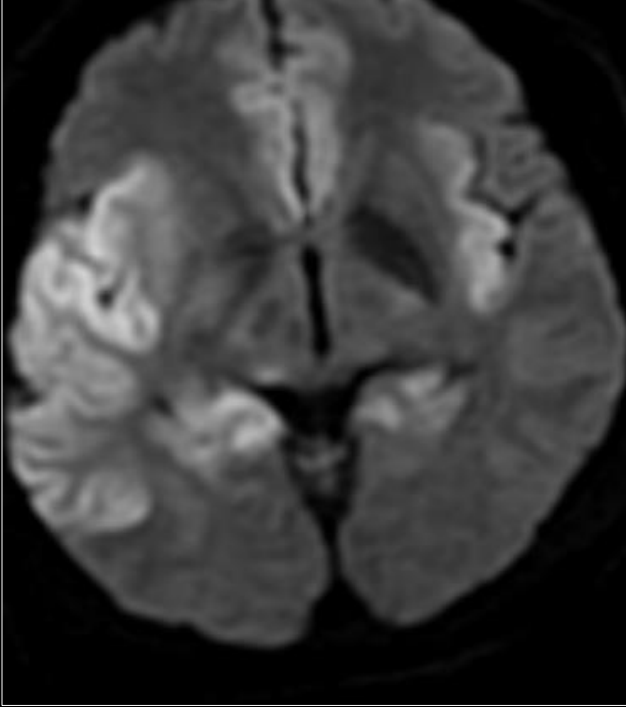
51y k, görme kaybı gelişen covid pozitif hastaya mukormikozis tanısı konuyor

9. Herpes Simplex Ensefaliti



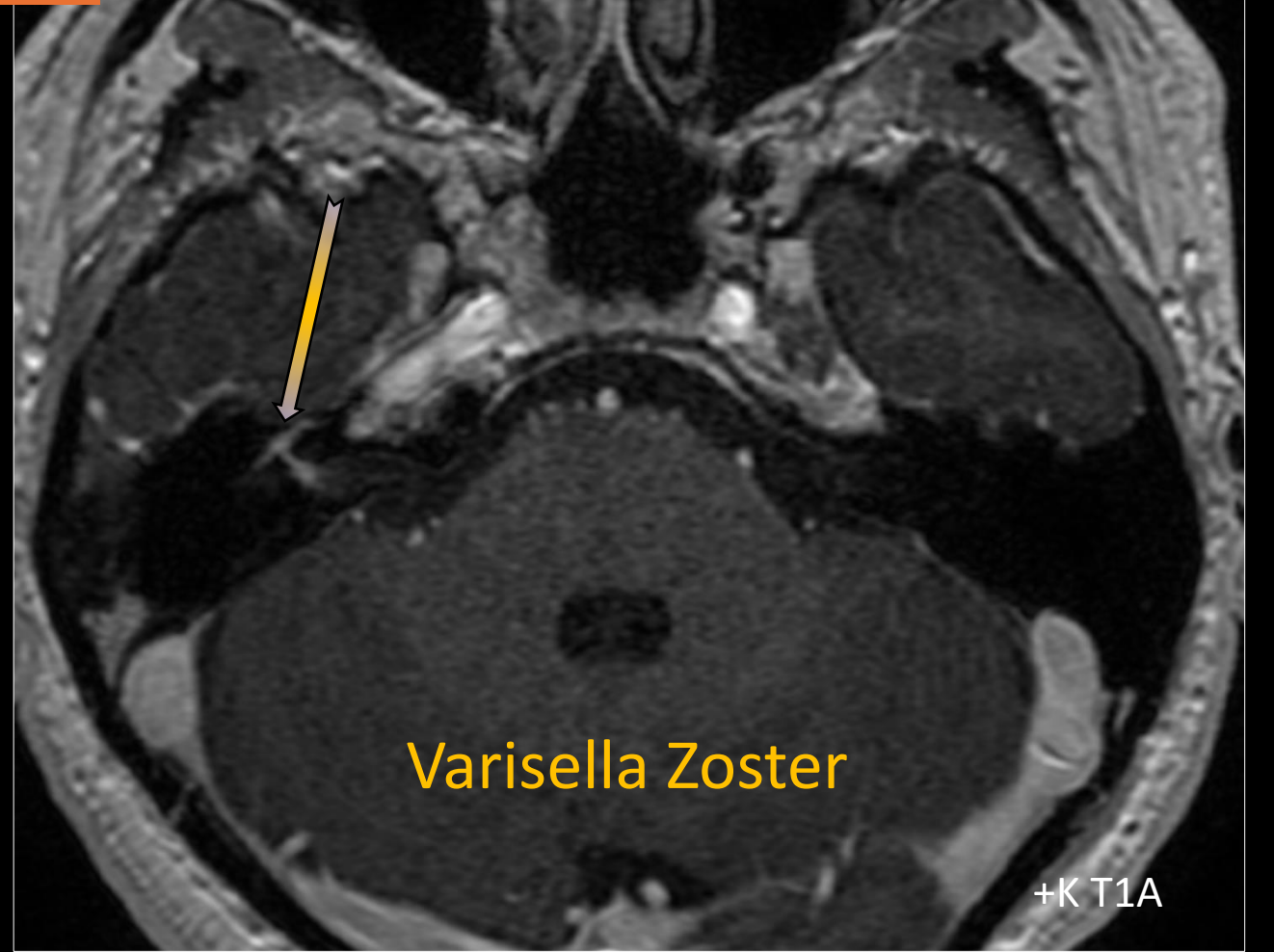
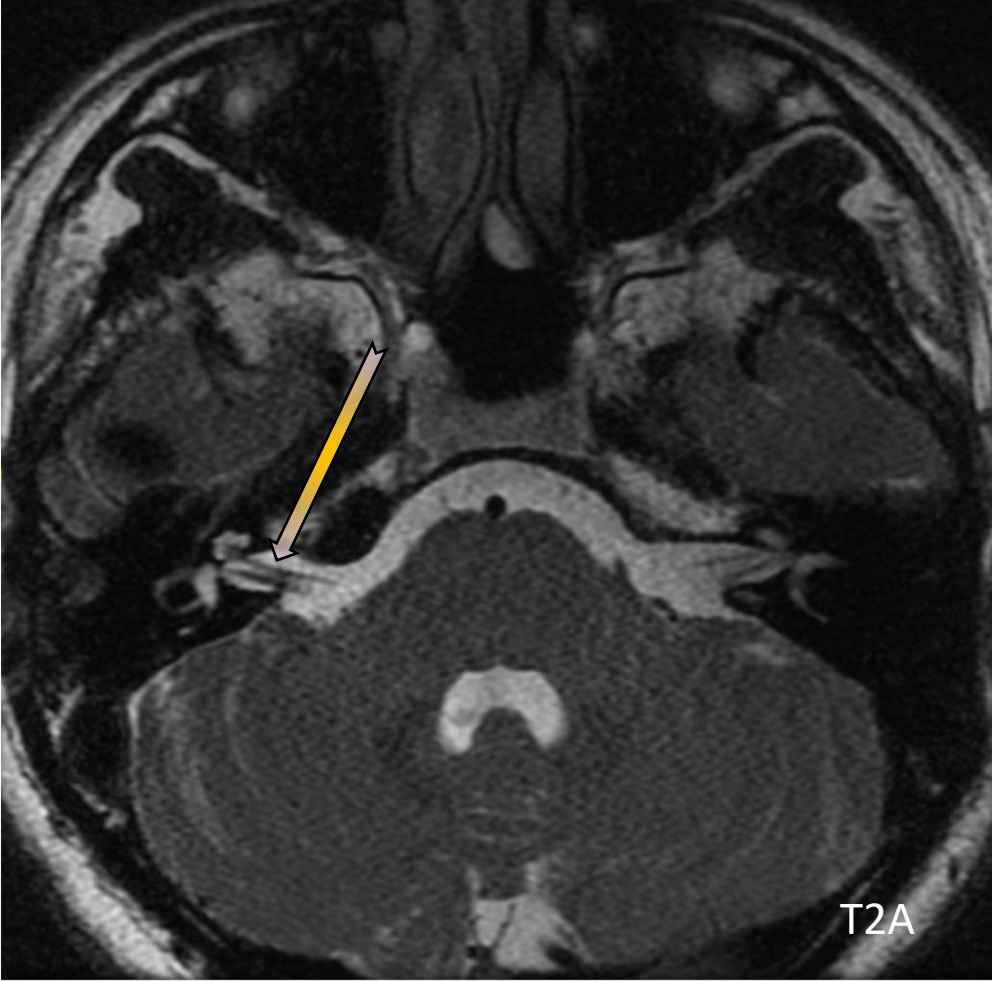
54y k hasta acil servise konuşma bozukluğu, bilinç değişikliği ve ateş yakınmalarıyla başvuruyor.

BOS'ta HSV1 pozitif ve EBV DNA pozitif



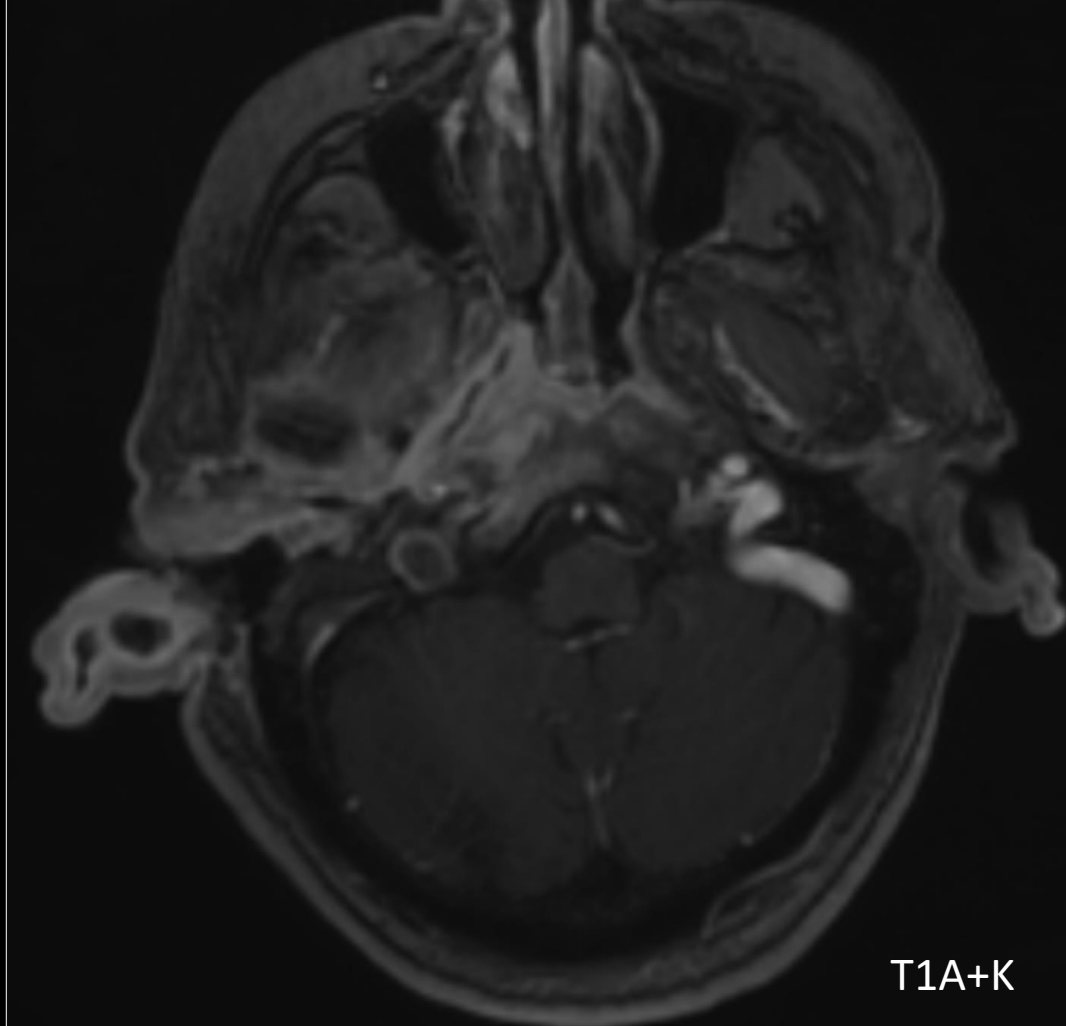
- Limbik sistemin hemorajik nekrotizan ensefaliti
- Anteromedial temporal lob, insuler korteks, subfrontal bölge ve singulat girus
- Bilateral ve asimetric
- **DWI**

10. Ramsay Hunt sendromu

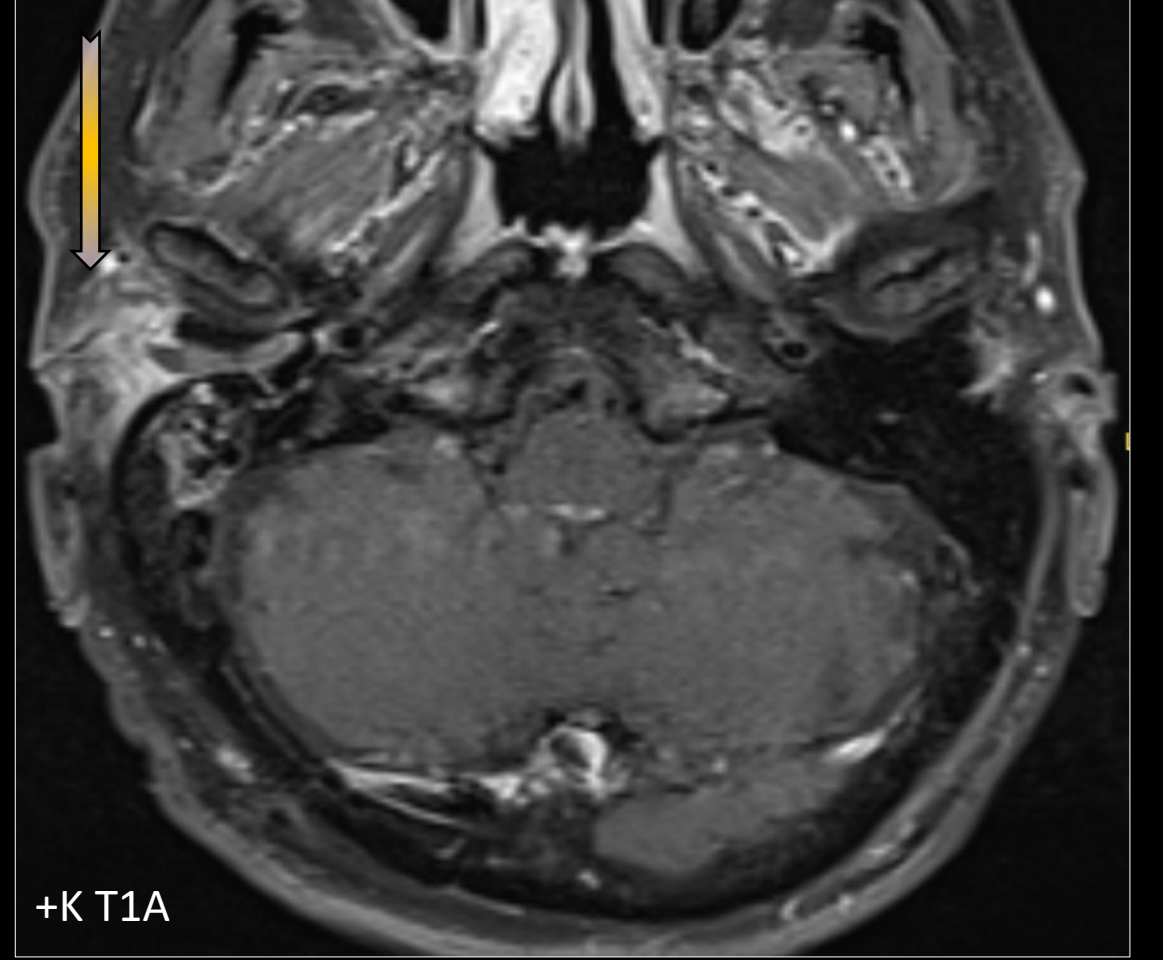
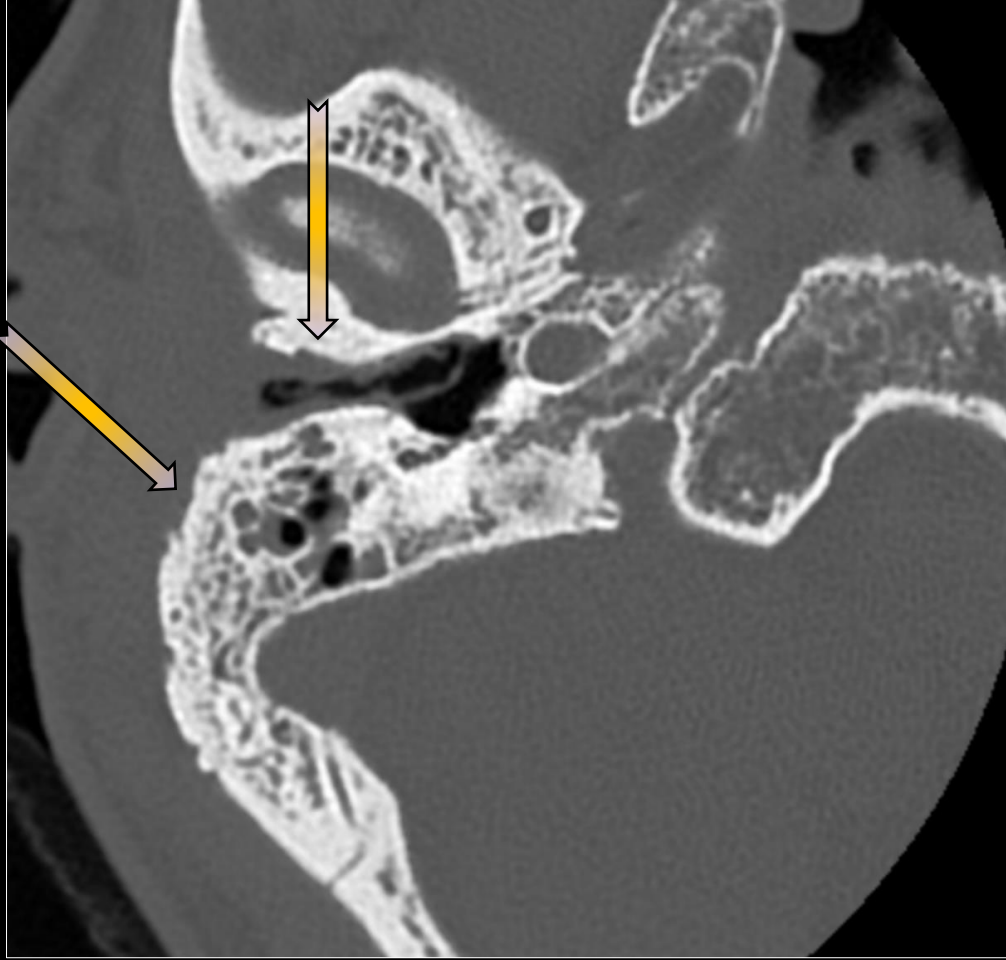


23y e, sađ yüz yarımında güçsüzlük, öyküde 1-2 gün önce kulakta döküntü ve şişlik, ÜSYE öyküsü
FM: Sađ dış kulak yolunda veziküler döküntüler ve Grade 4 fasiyal paralizi
Tedavi: 5 gün IV Asiklovir

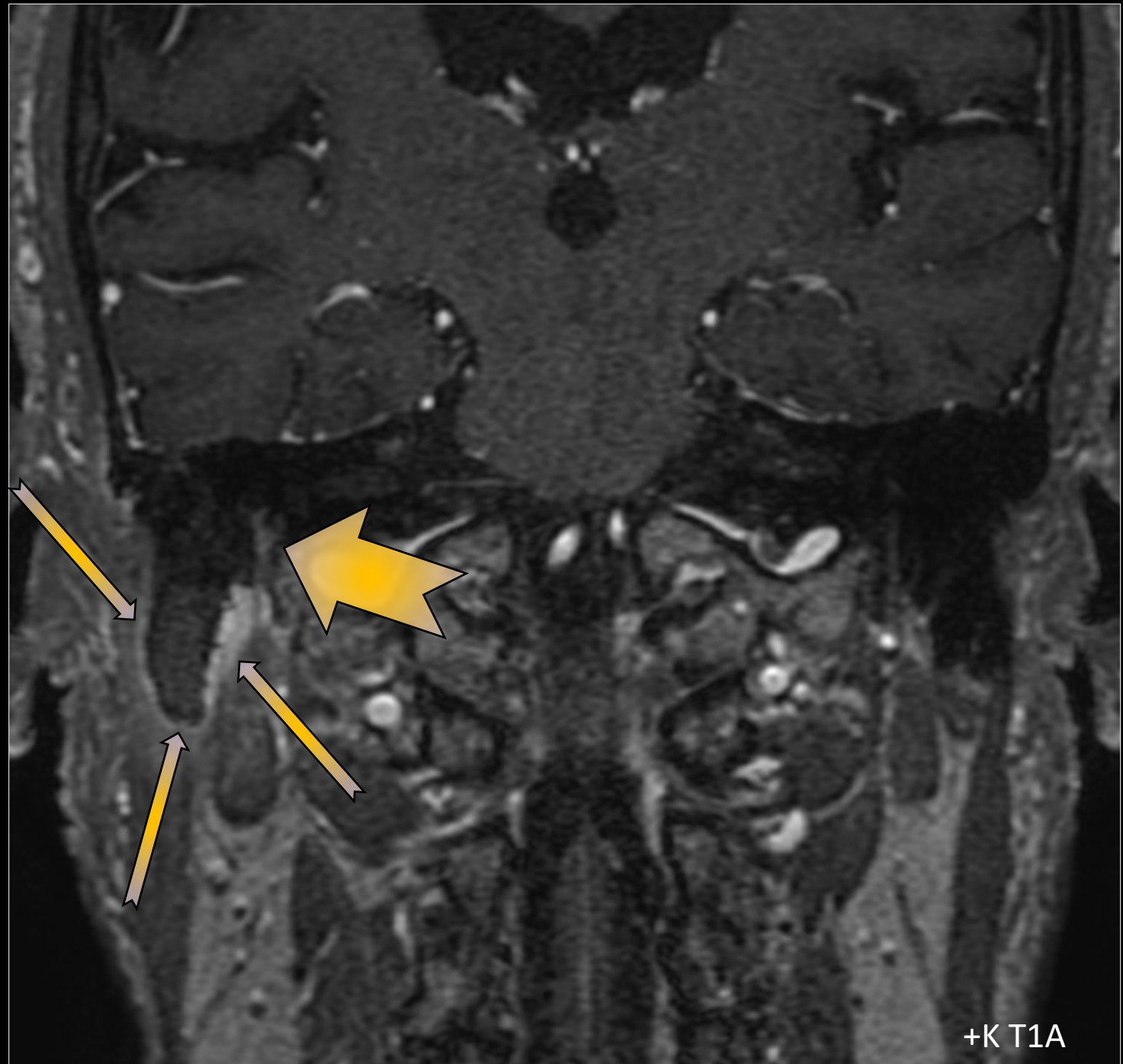
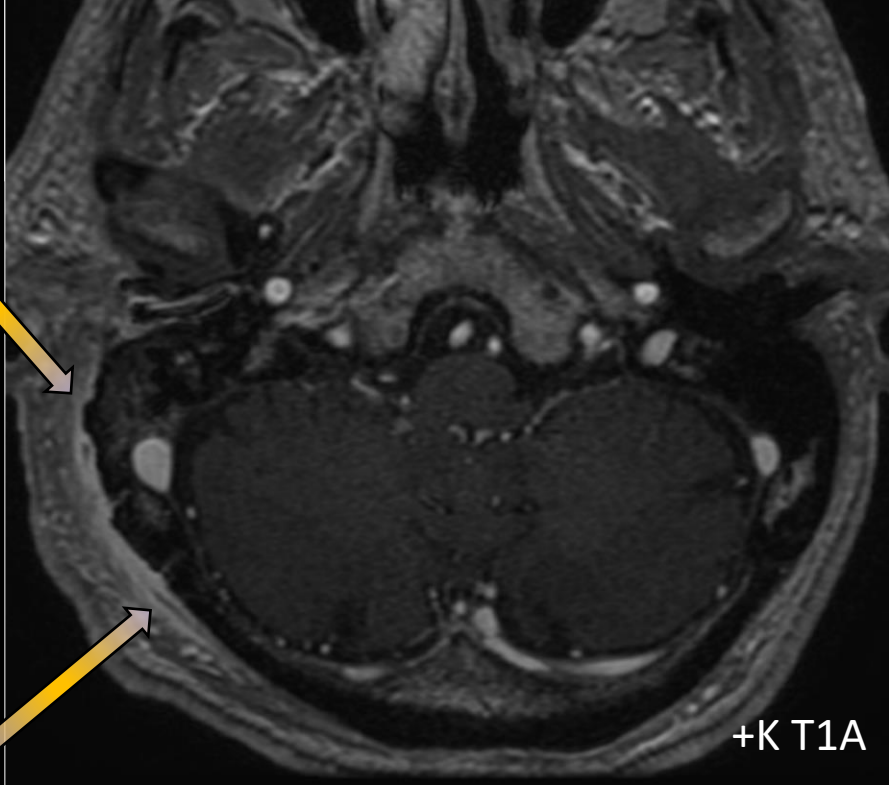
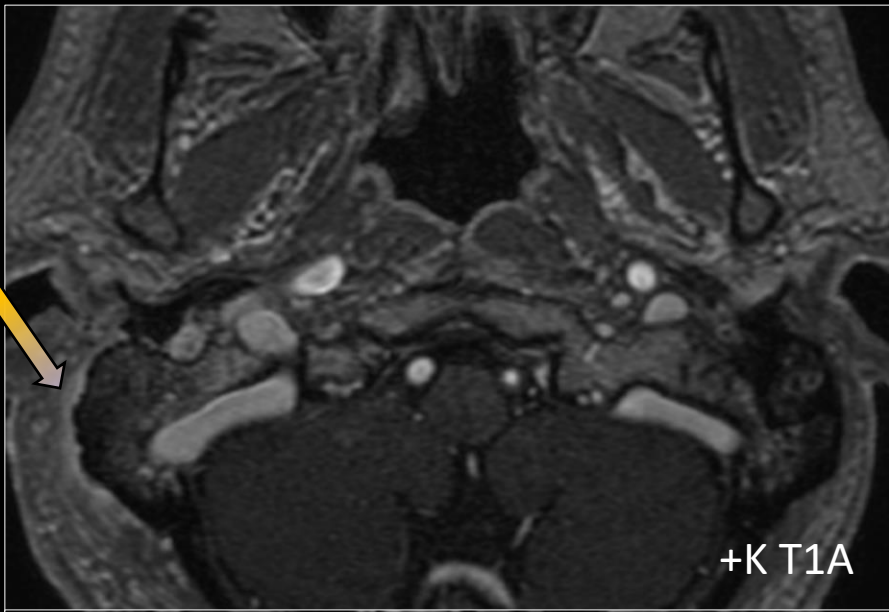
11.Malign Eksternal Otit



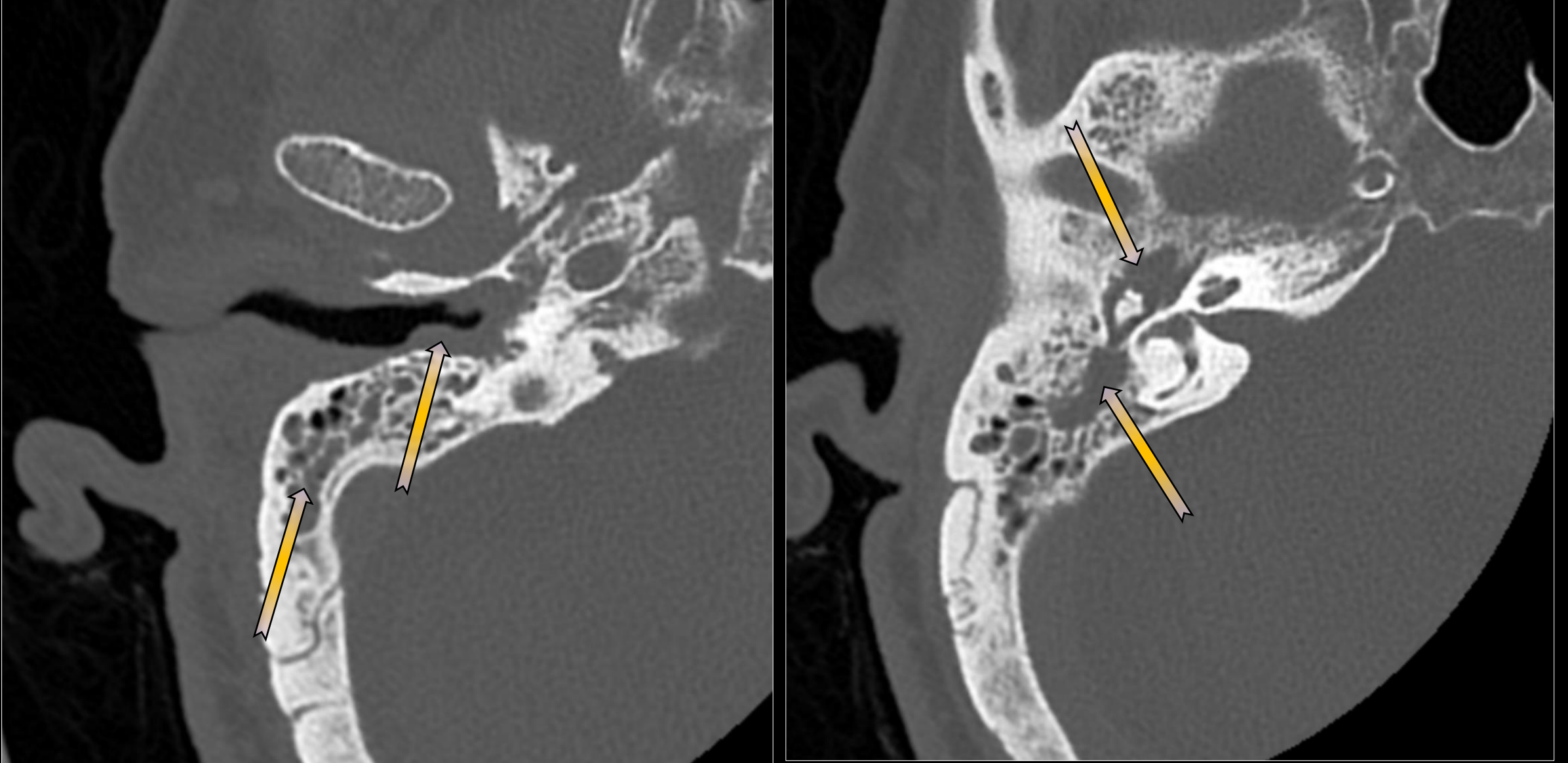
- ✓ DKY ve komşu yumuşak dokular
- ✓ Kafa tabanı
- ✓ %95 Pseudomonas aeruginosa
- ✓ Yaşlı ve diabetik hastada kulak ağrısı ve otore
- ✓ Kranial sinir felci (7,9,10 ve 11)
- ✓ Yumuşak dokularda kalınlaşma, kontrastlanma
- ✓ DKY, temporal kemik, TME ve klivusta erozyon
- ✓ Flegmon veya apse
- ✓ Orta kulak, petröz apeks, TME, mastikator alan, karotid alan ve nazofarengeal yumuşak dokular



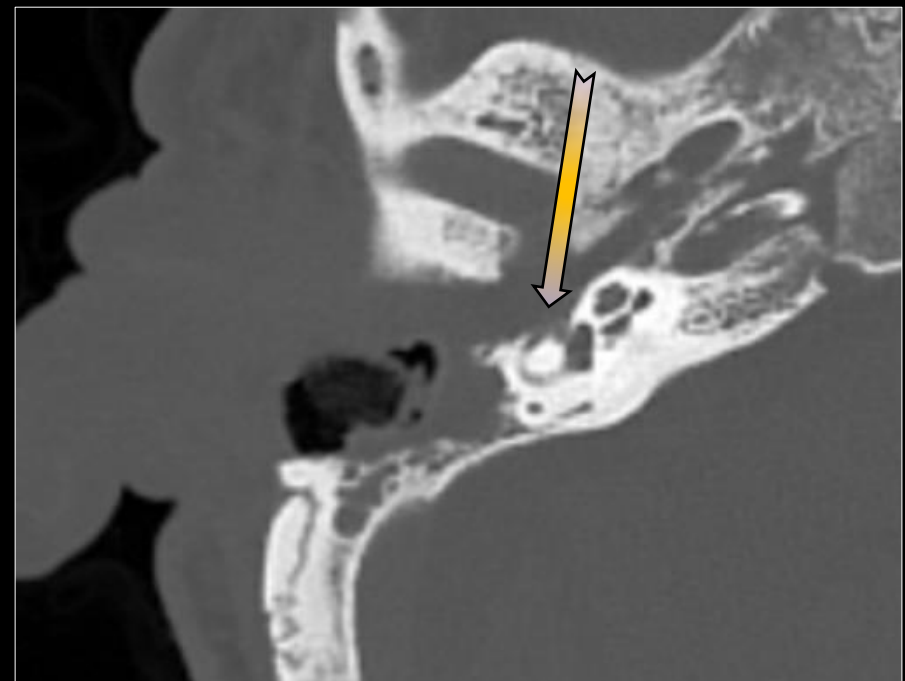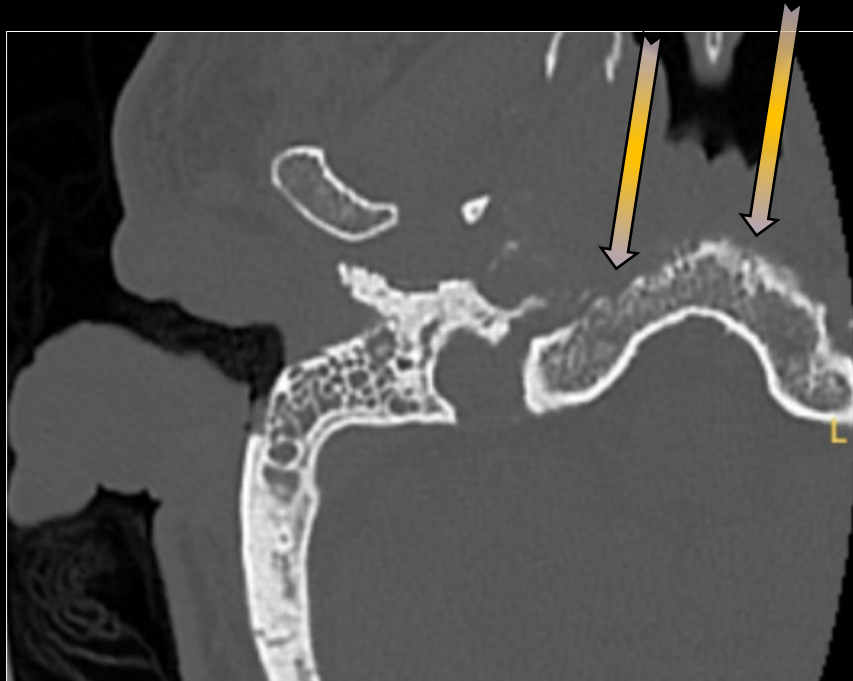
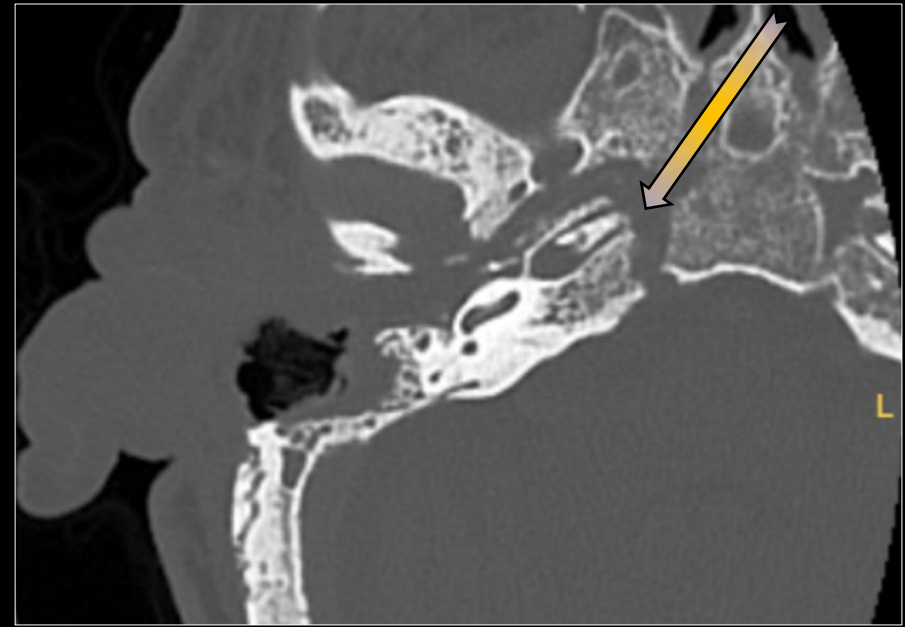
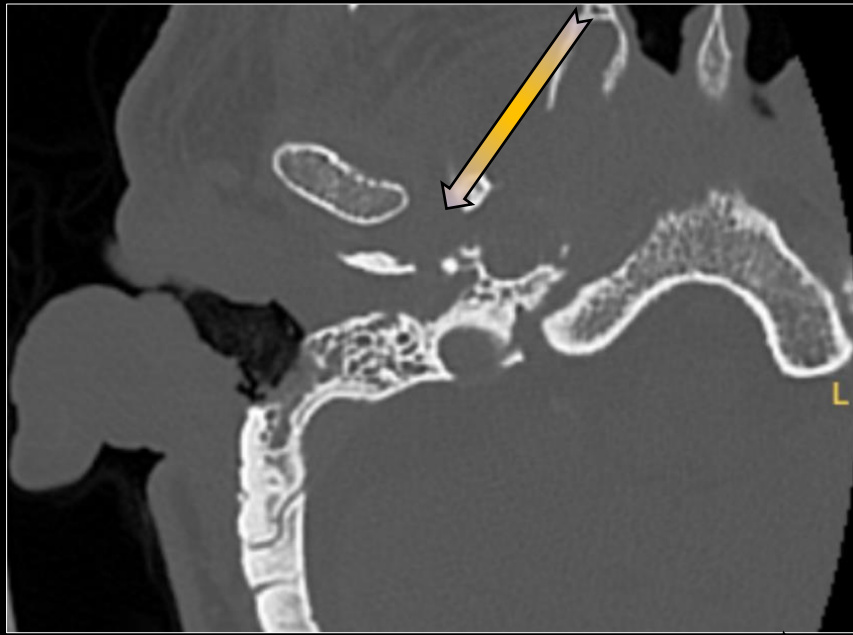74y e, kaplıca sonrası dış kulak yolu enfeksiyonu, diabet hastası, fasiyal paralizi ile acil servise başvuruyor.

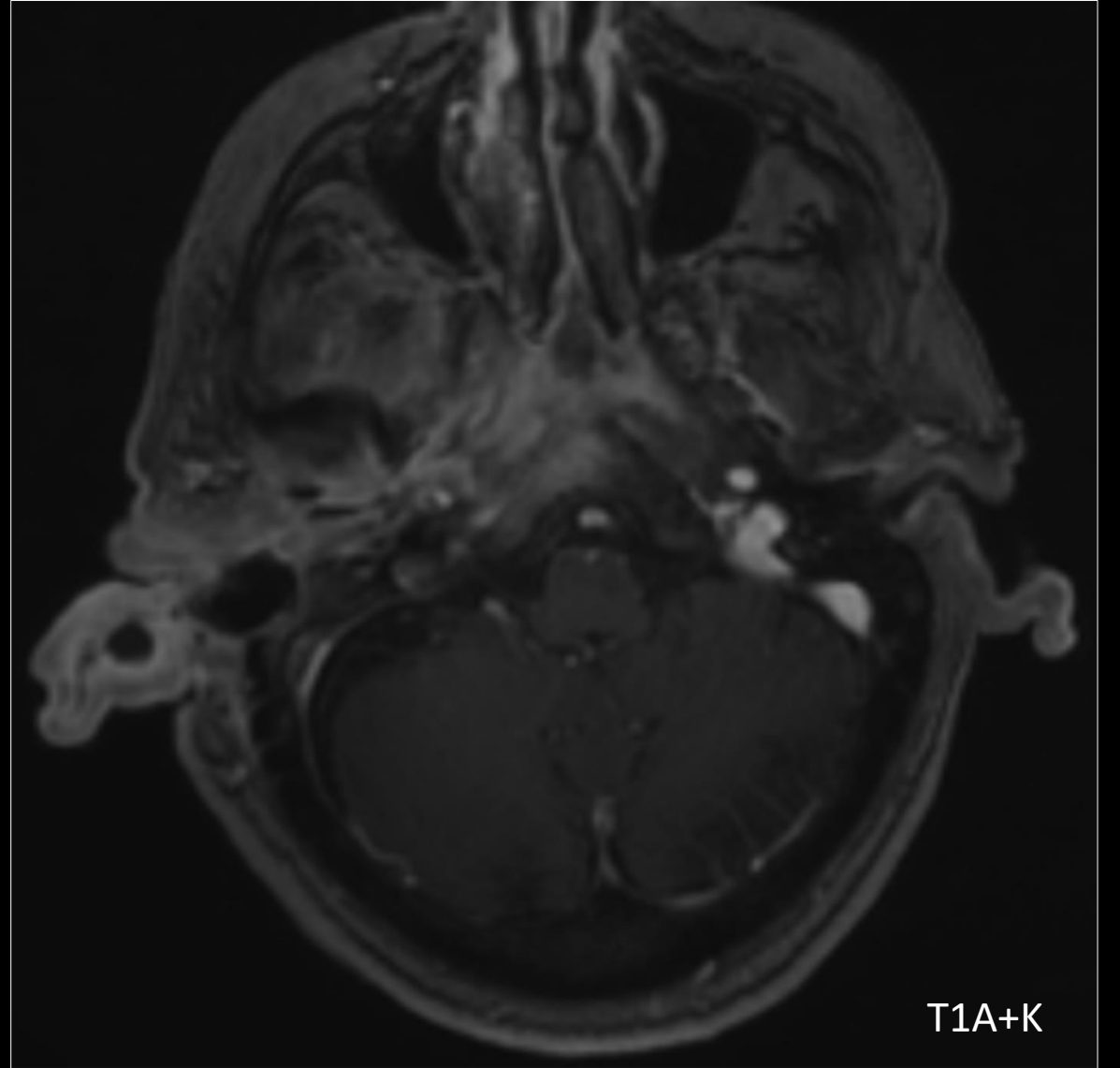
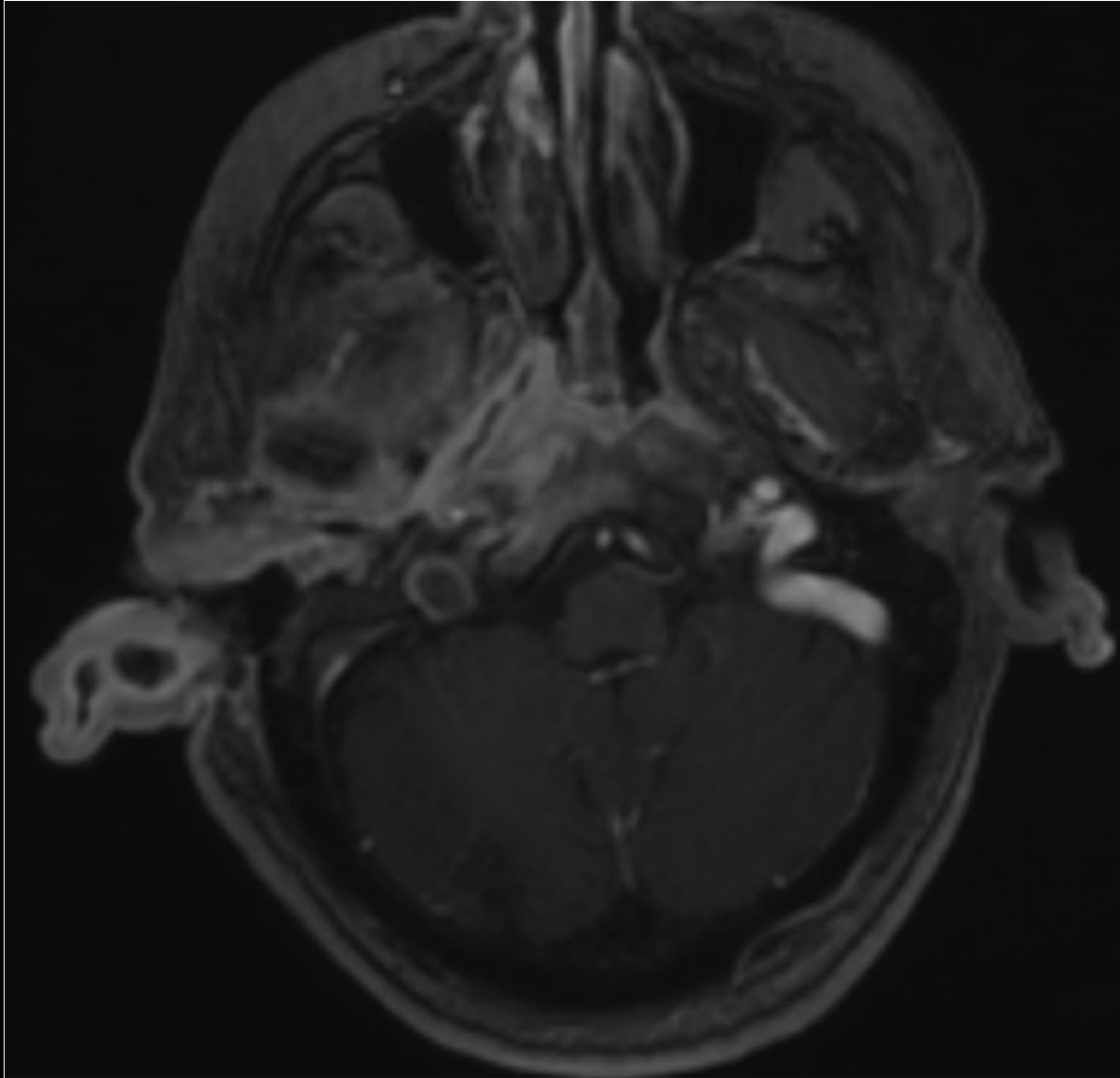


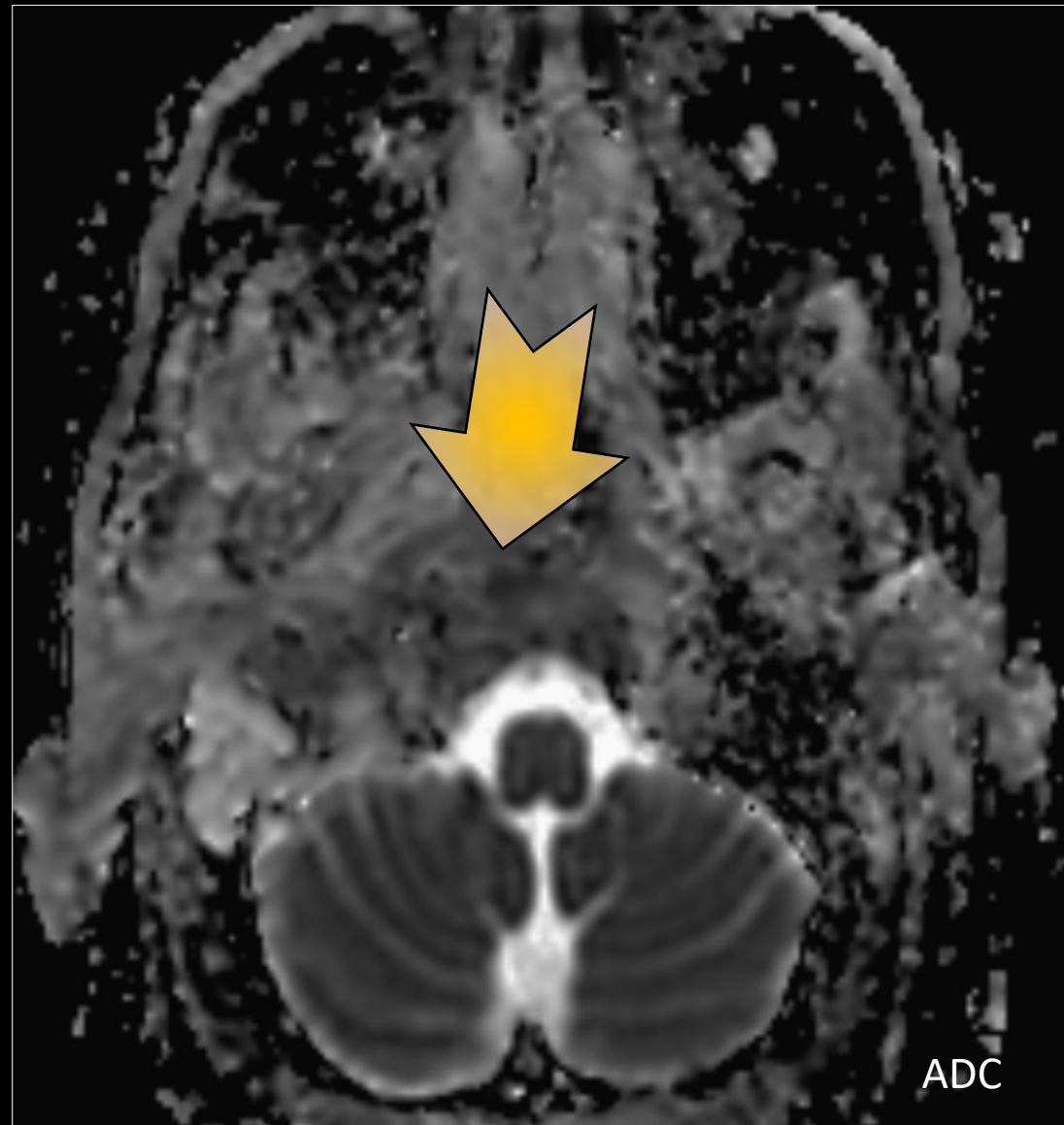
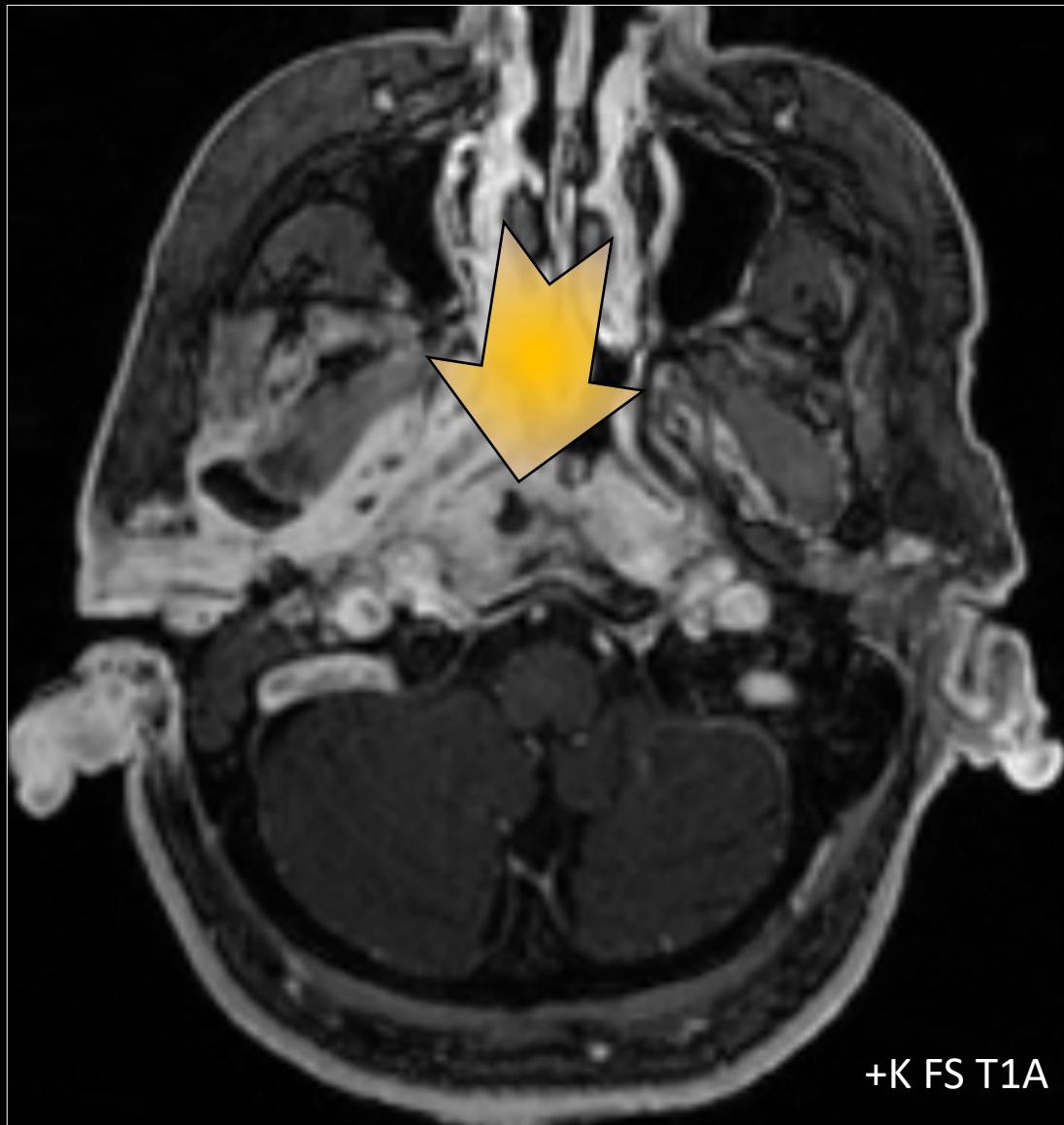12.Malign Eksternal Otit



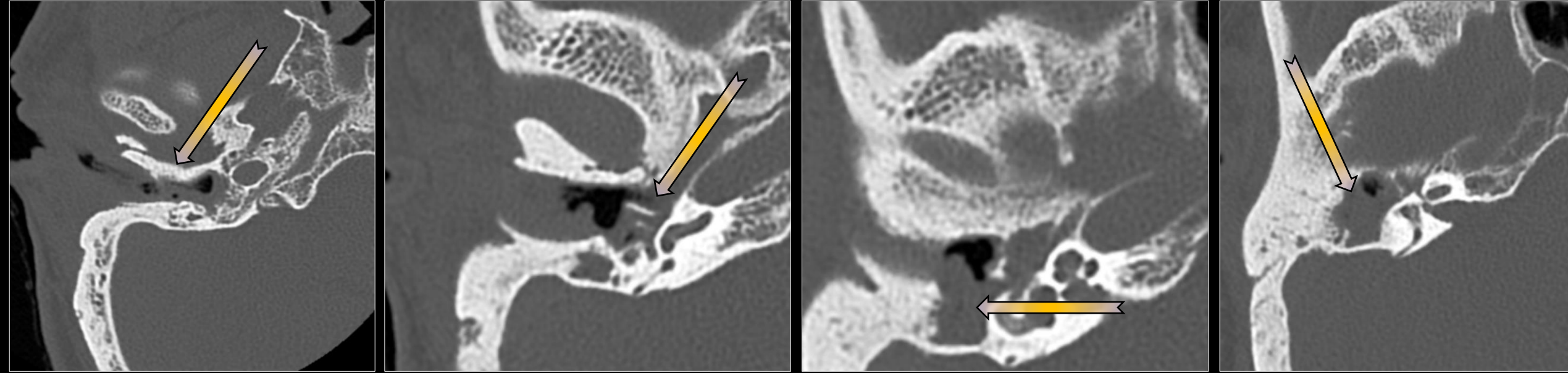
86y k, sađ kulakta ađrı ve akıntı. Diabet hastası. Acil radikal mastoidektomi.



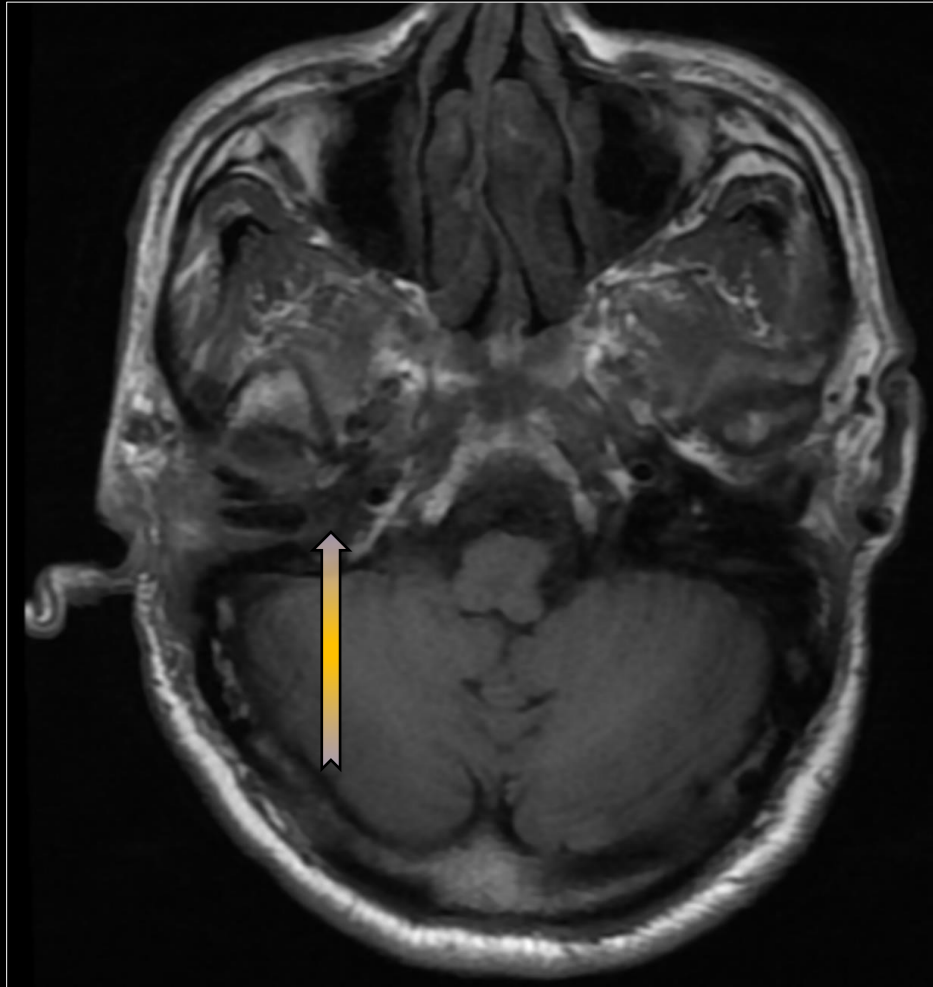




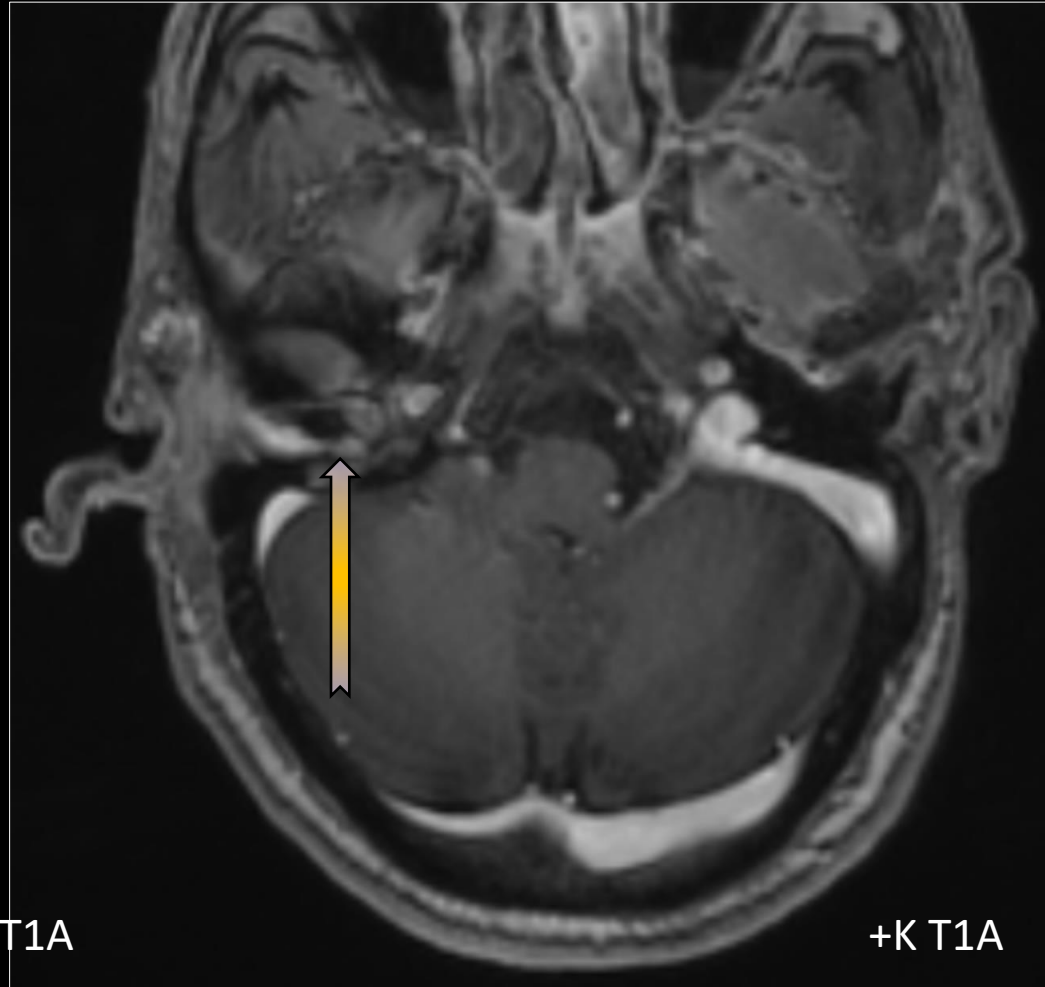
13. Yabancı cisim



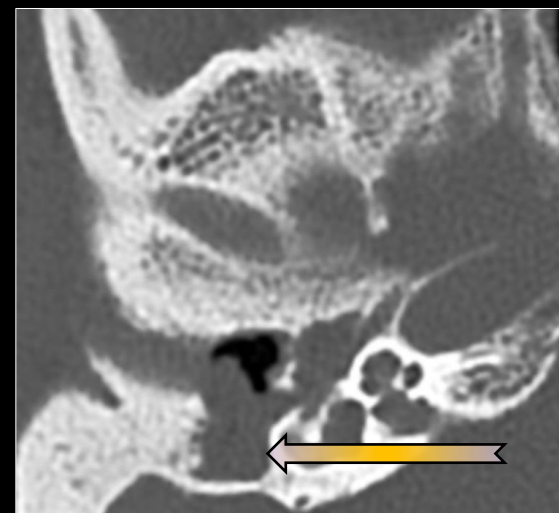
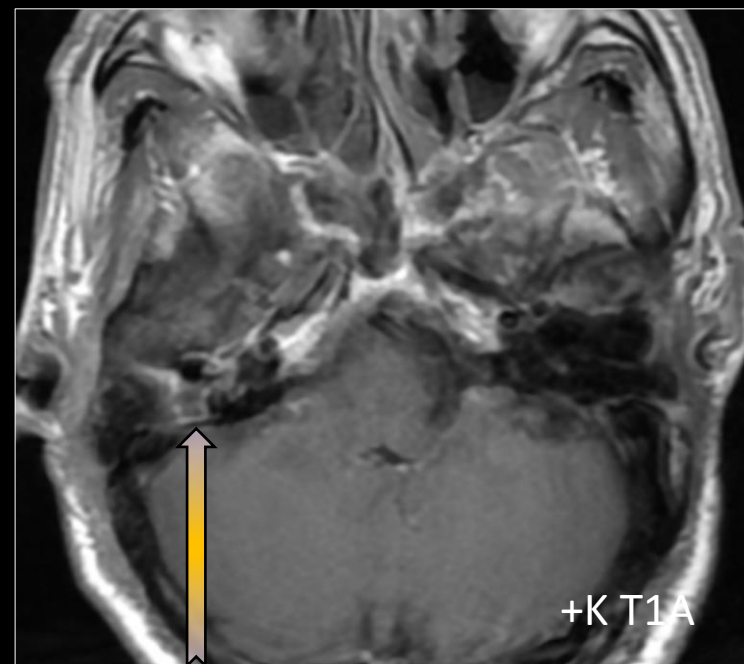
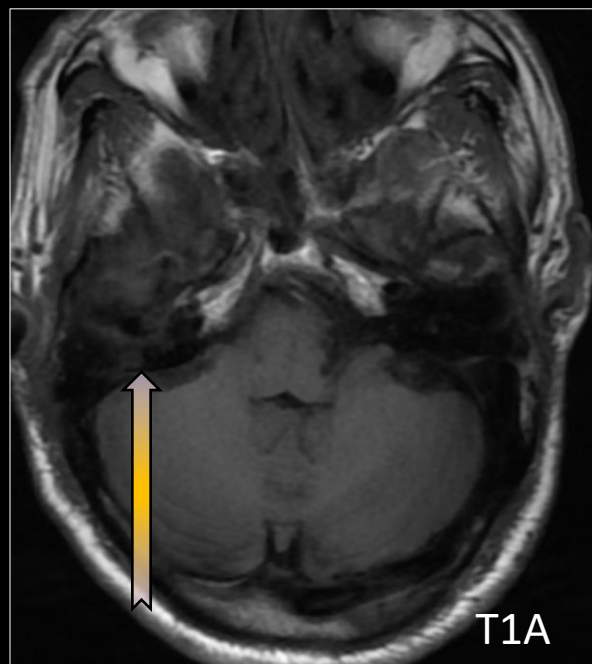
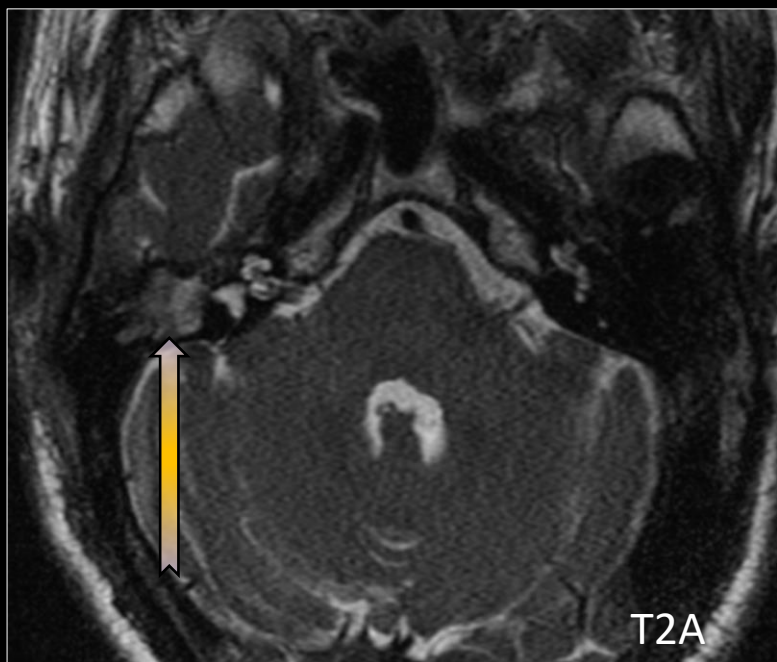
82y e, kulak miyazı hastası. Sinek larvalarının kulağa yerleşmesi sonucu oluşur.



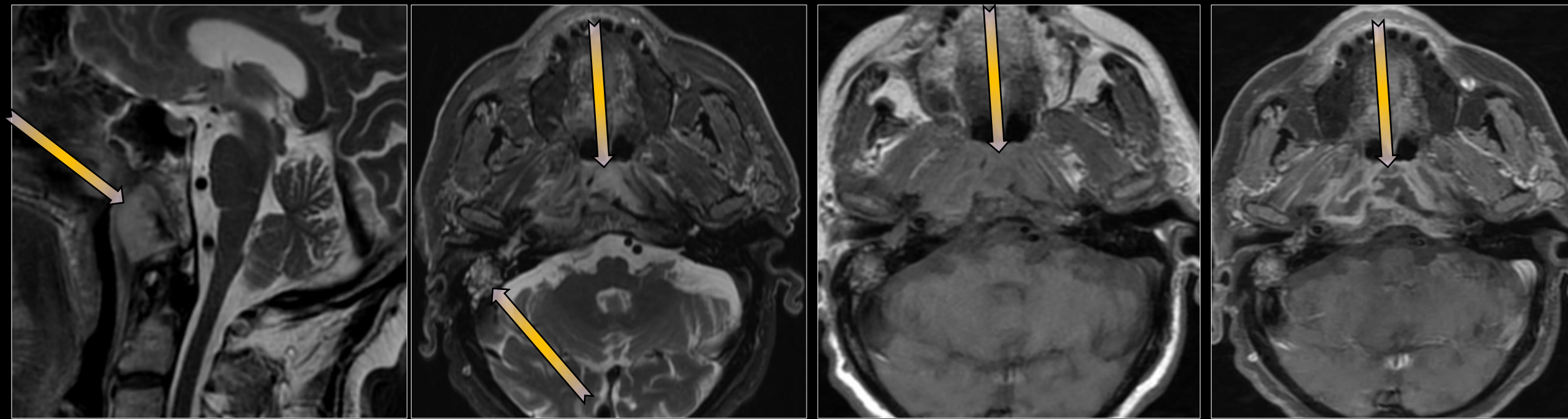
T1A



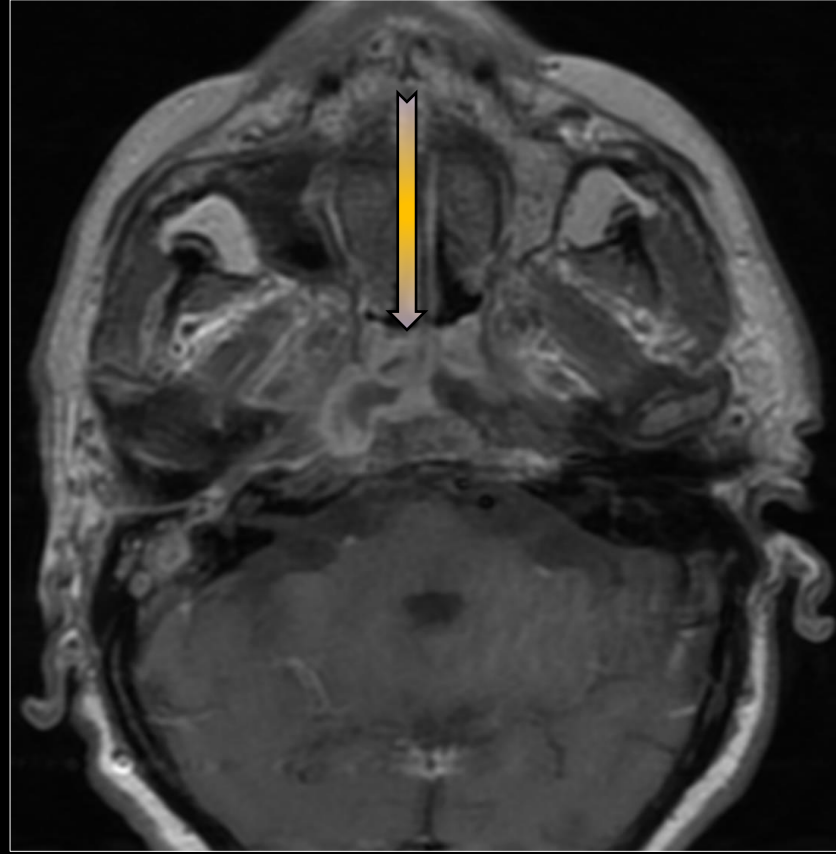
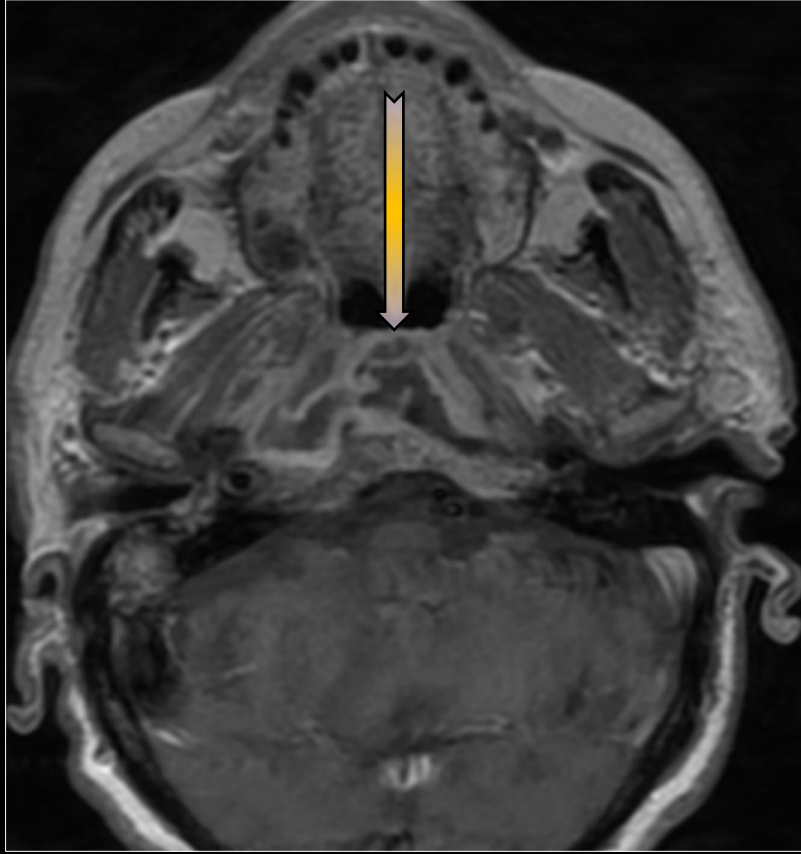
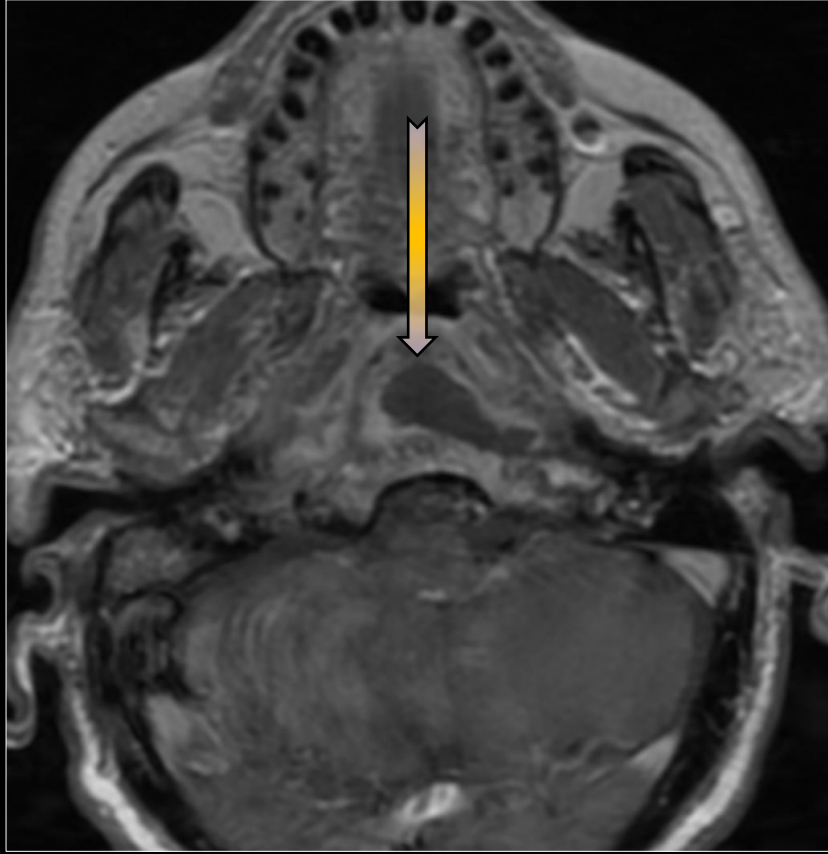
+K T1A



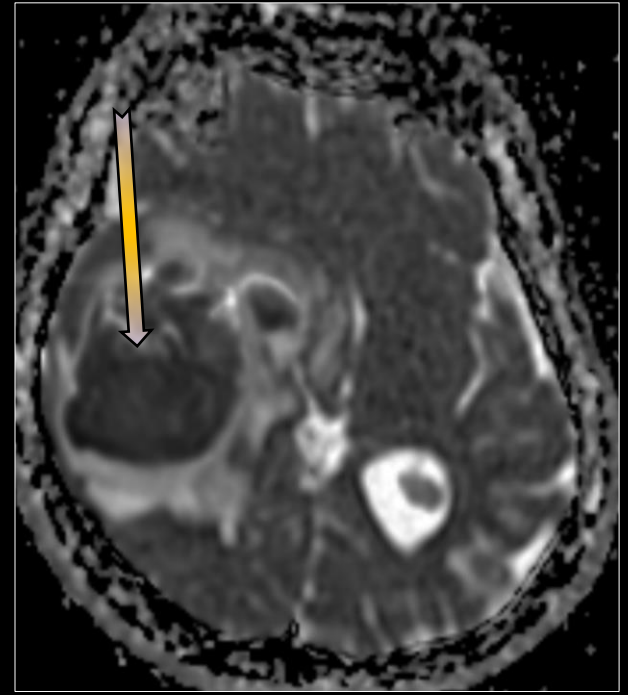
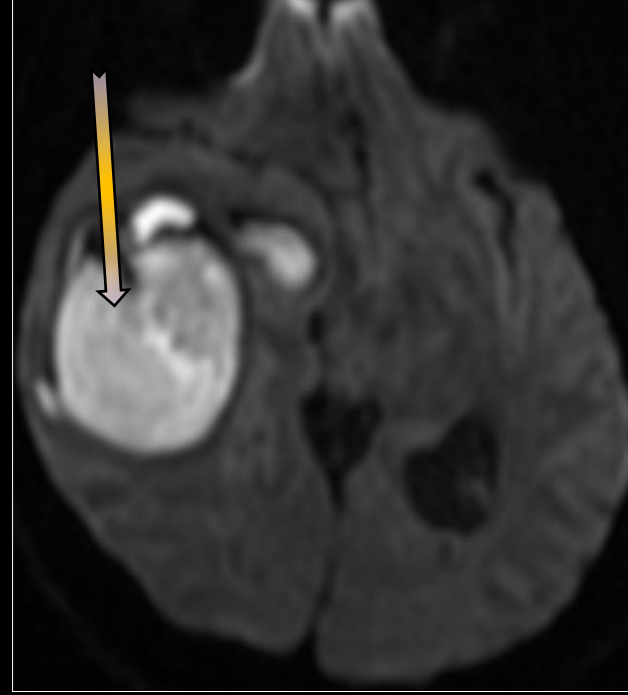
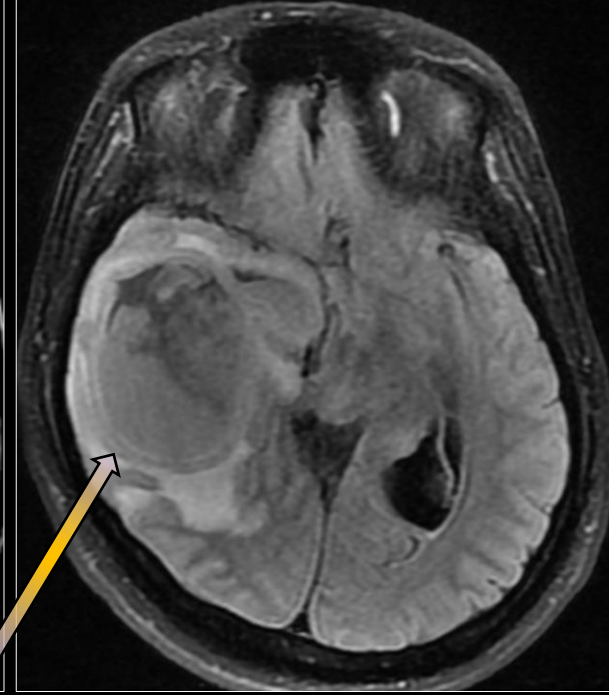
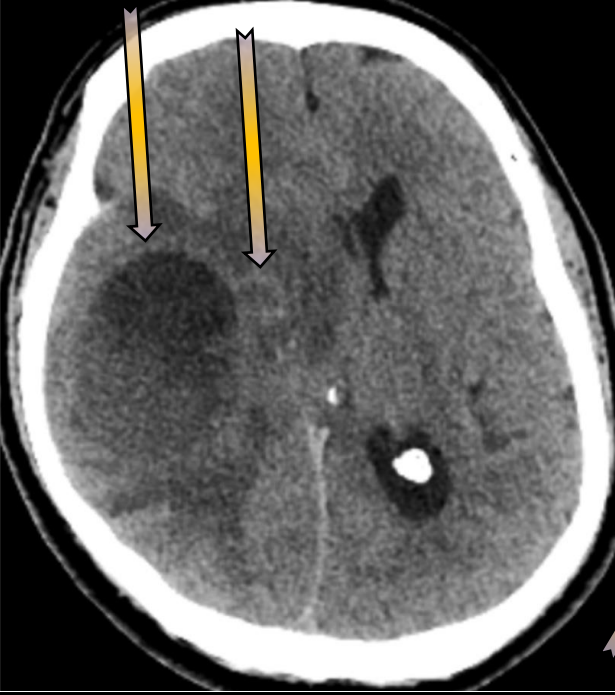14. Nazofarenks absesi



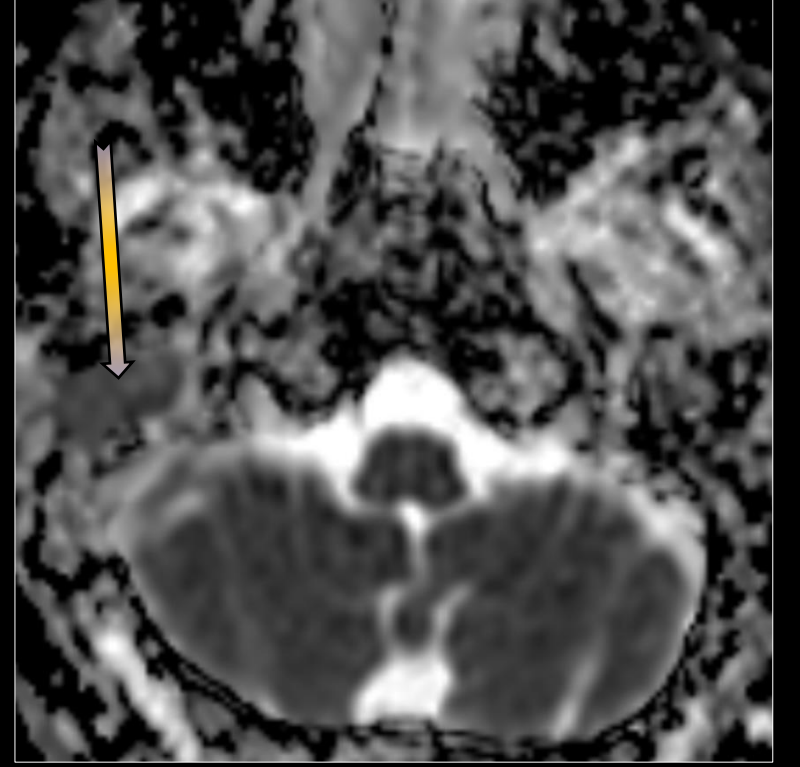
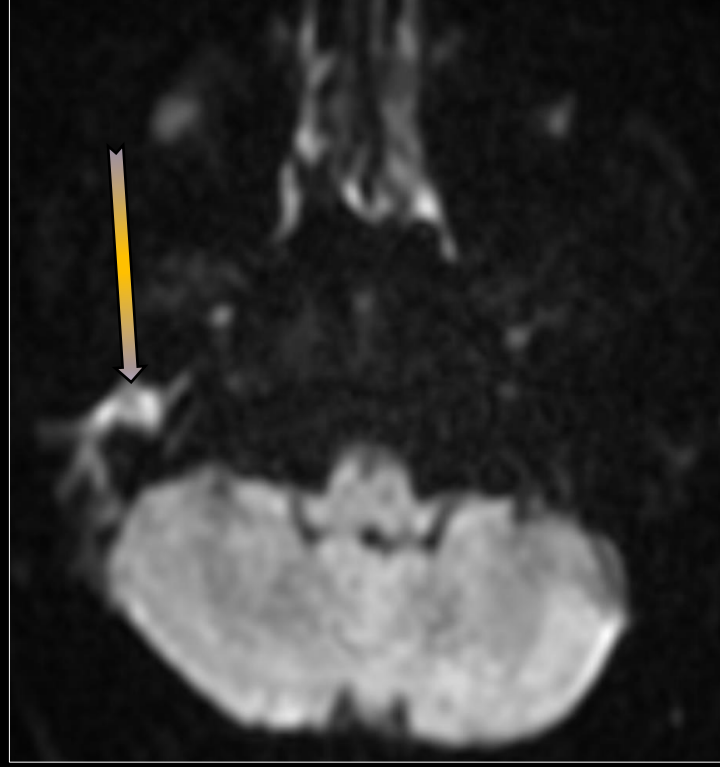
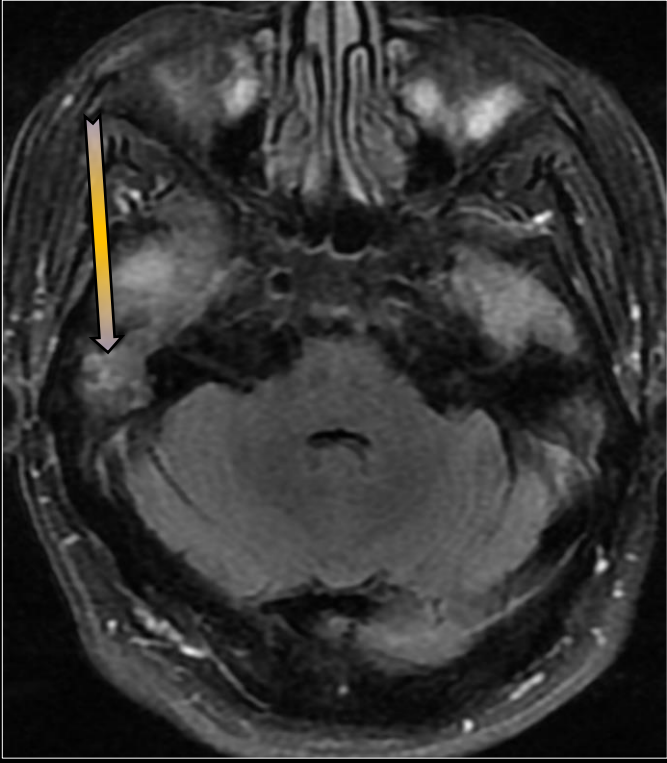
87y e



15. Beyin absesi

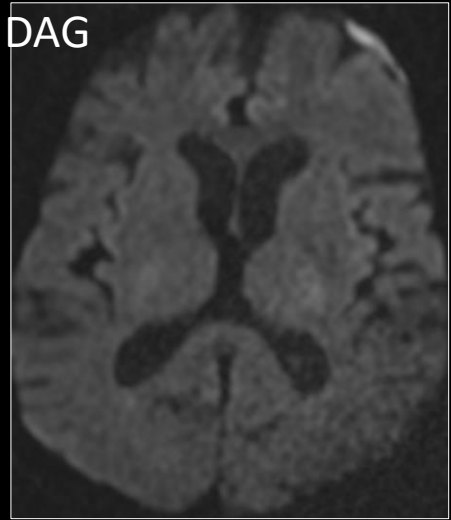
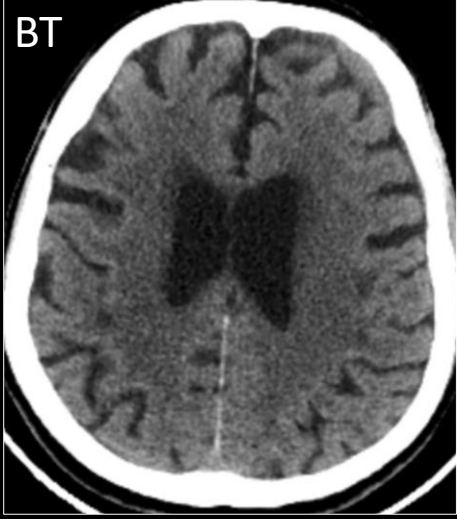


44y e hasta bilinç bulanıklığı ve ekstremlerde güç kaybı yakınması ile acil servise başvuruyor. Kulak akıntısı öyküsü var.

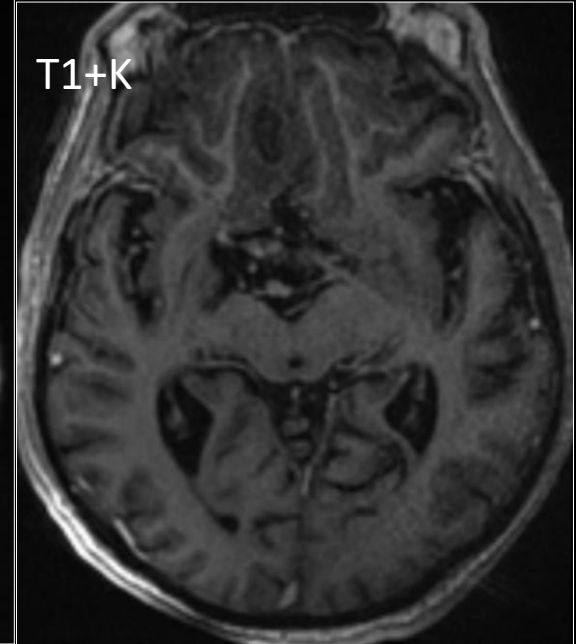
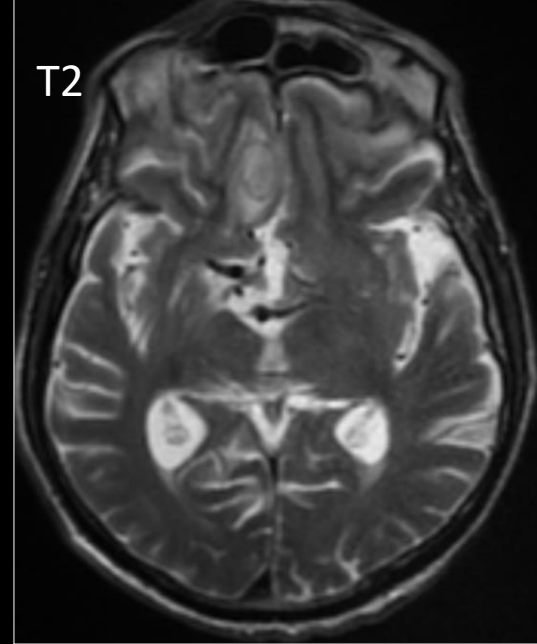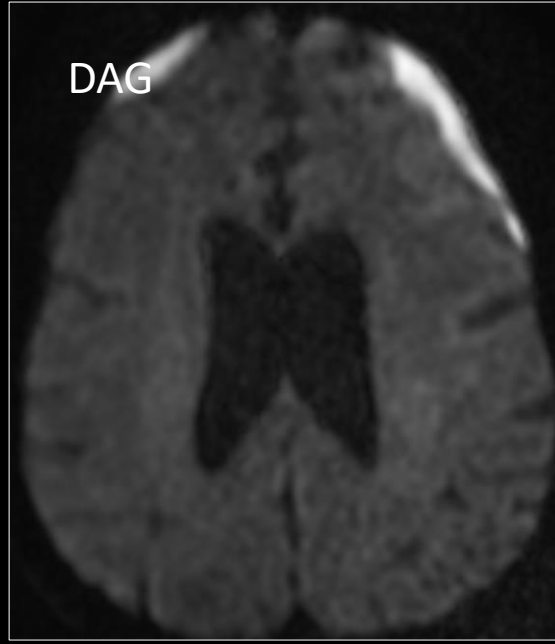
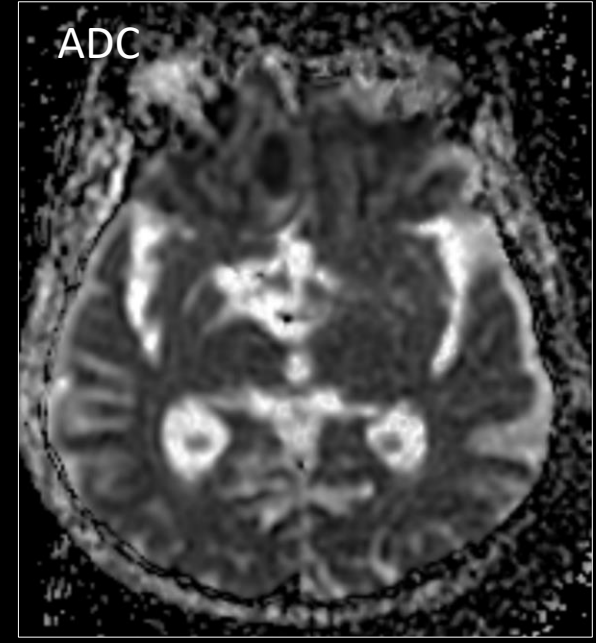
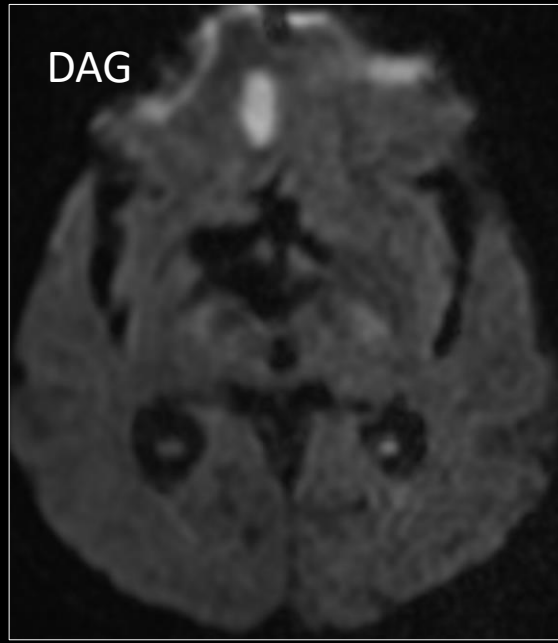


Histopatolojik tanı: Beyin apsesi, temporal apse ve dış kulak yolu ile orta kulakta kolesteatom

16. Beyin absesi

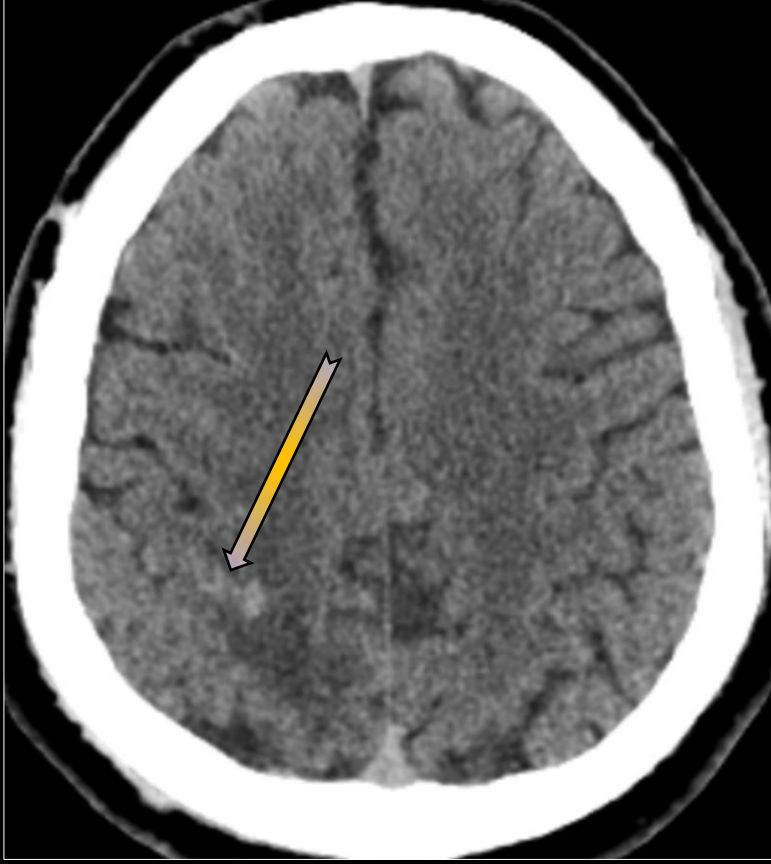


Acile geliş



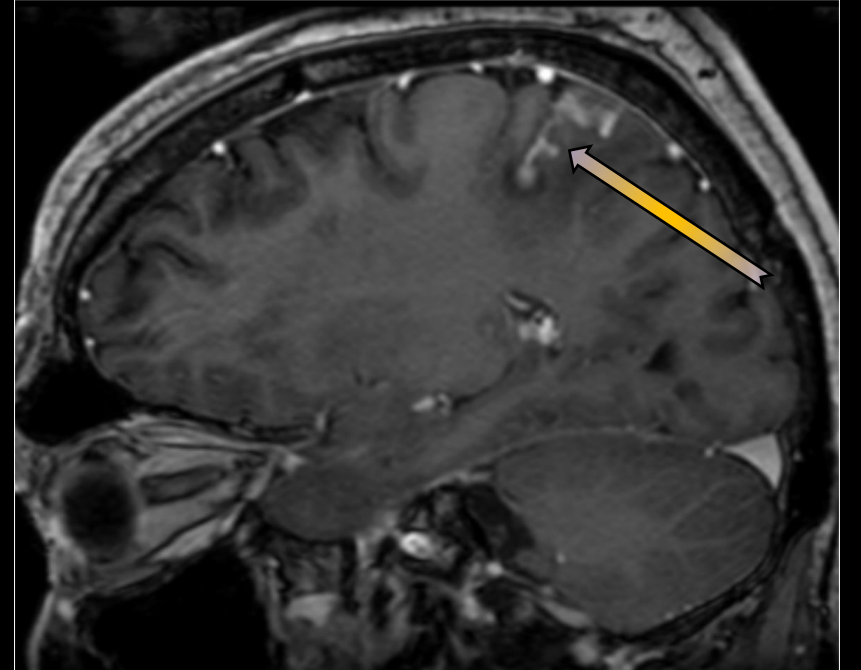
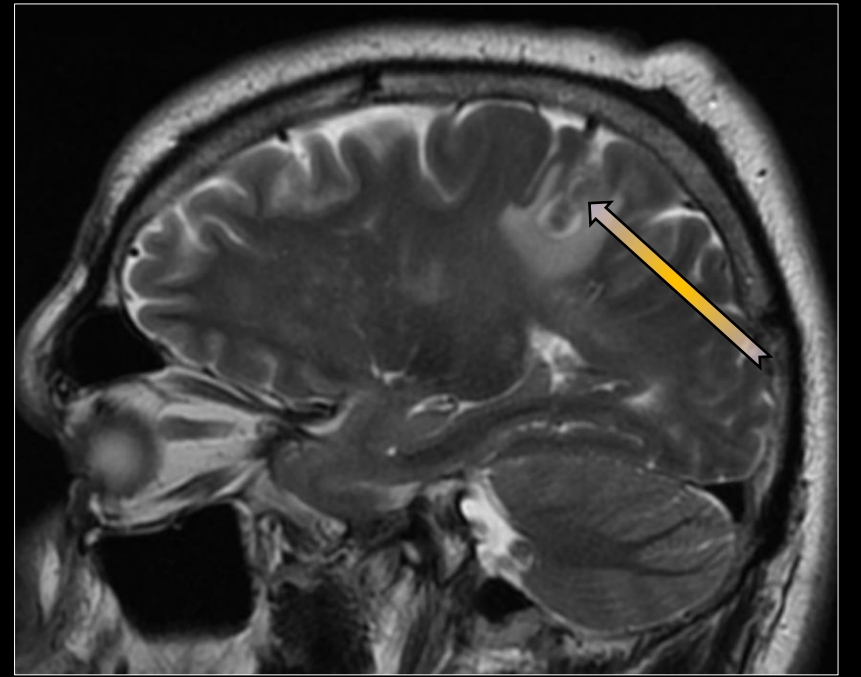
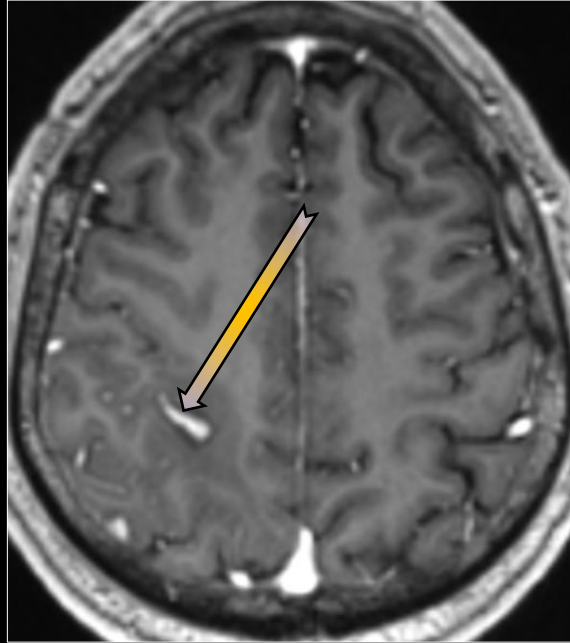
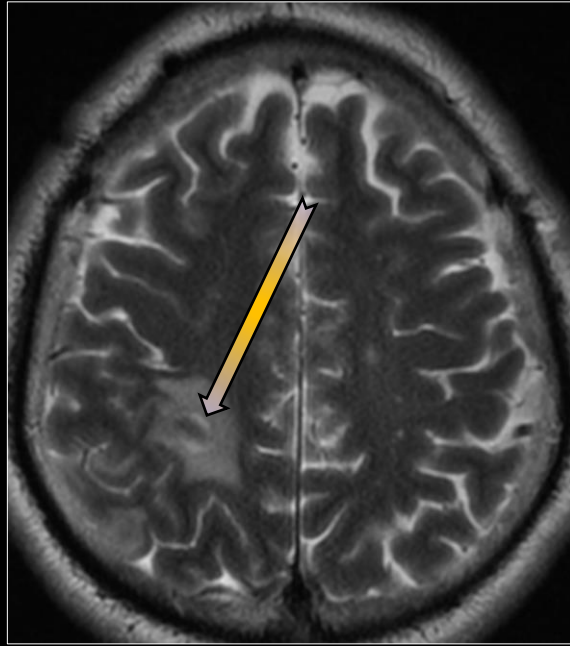
81y e, kan kültürü:Gr+kok

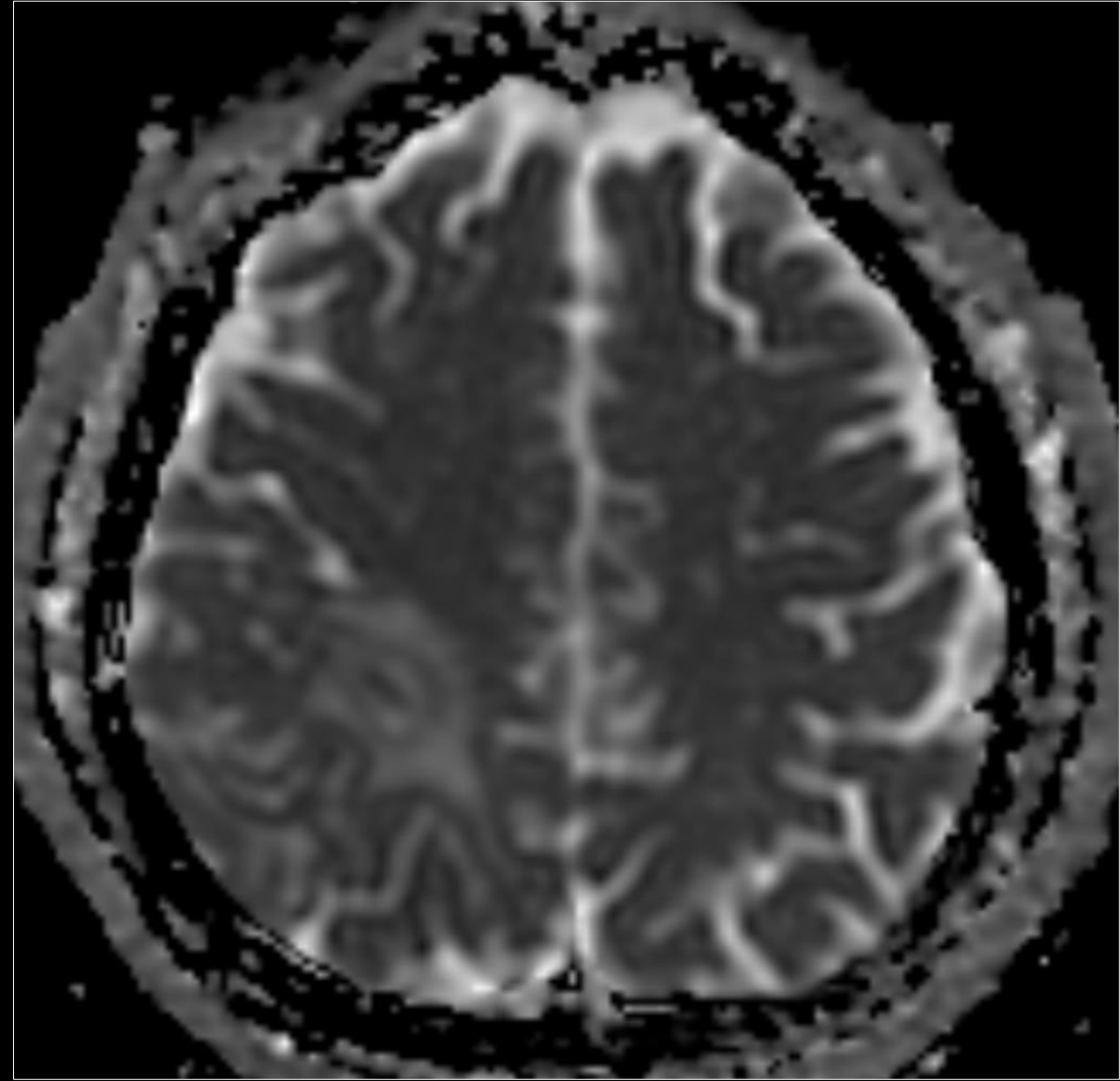
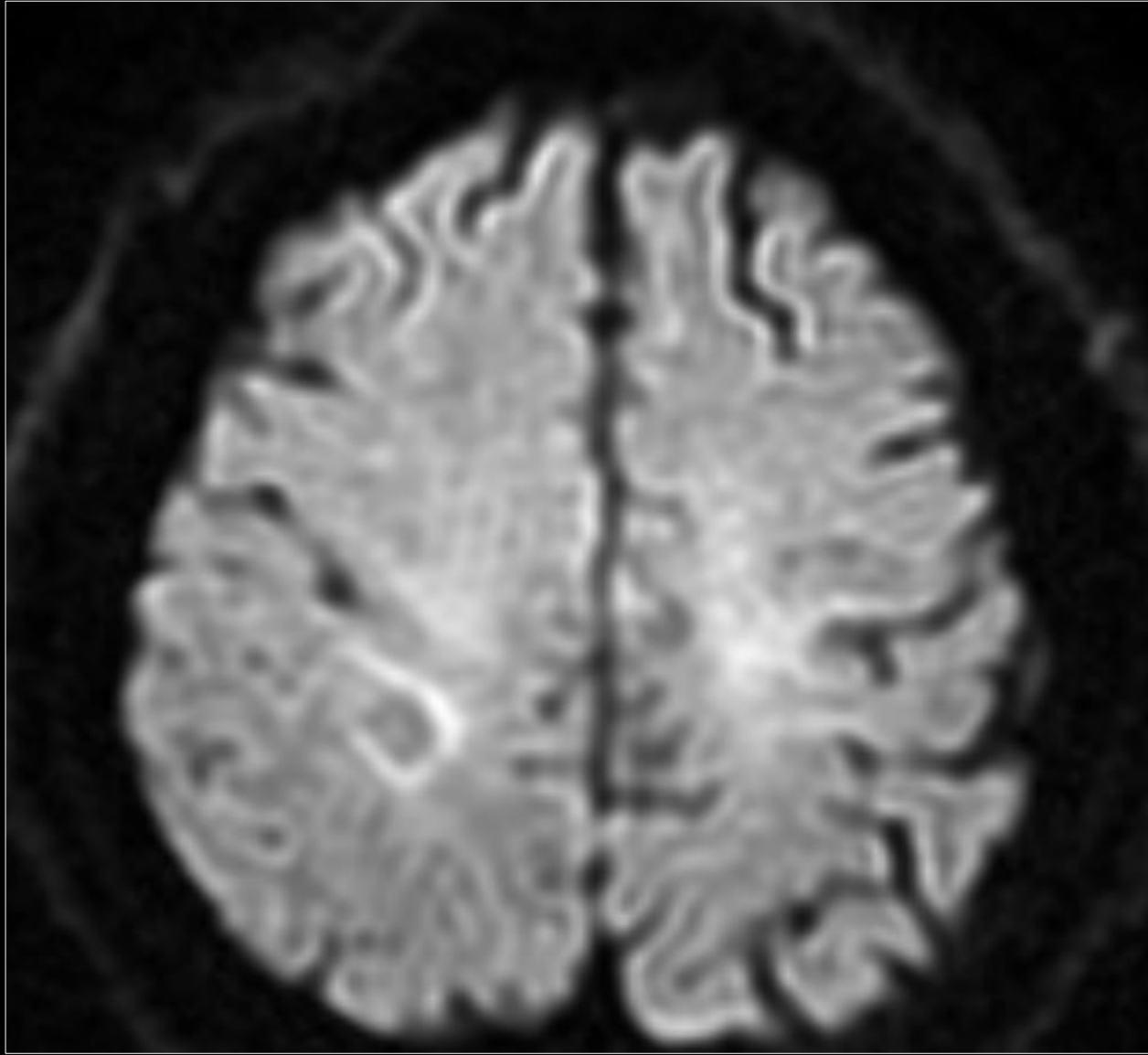
17. Tüberküloz



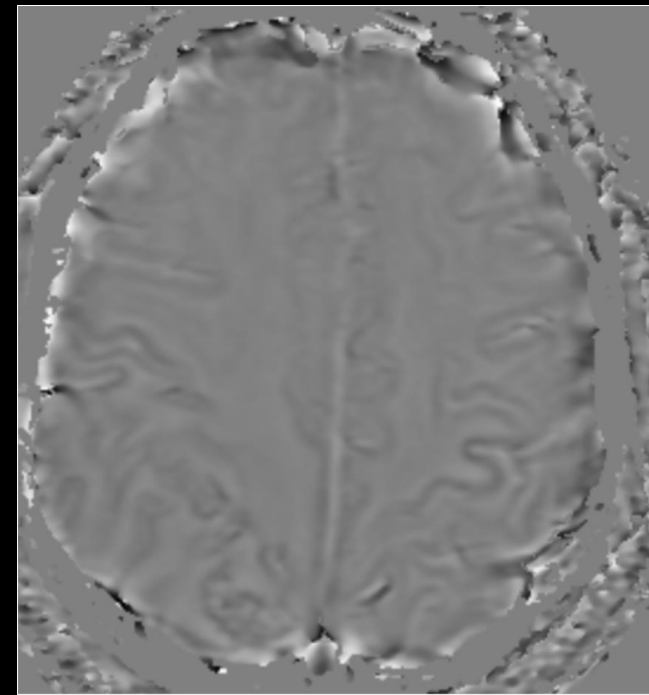
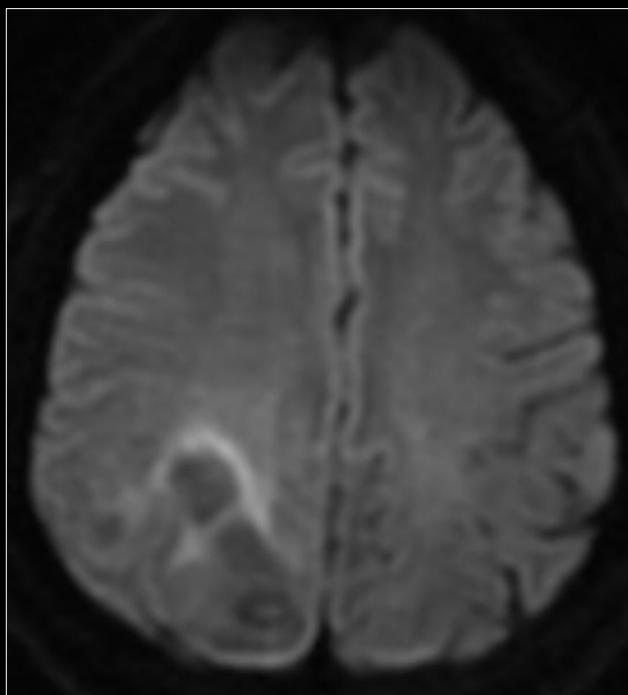
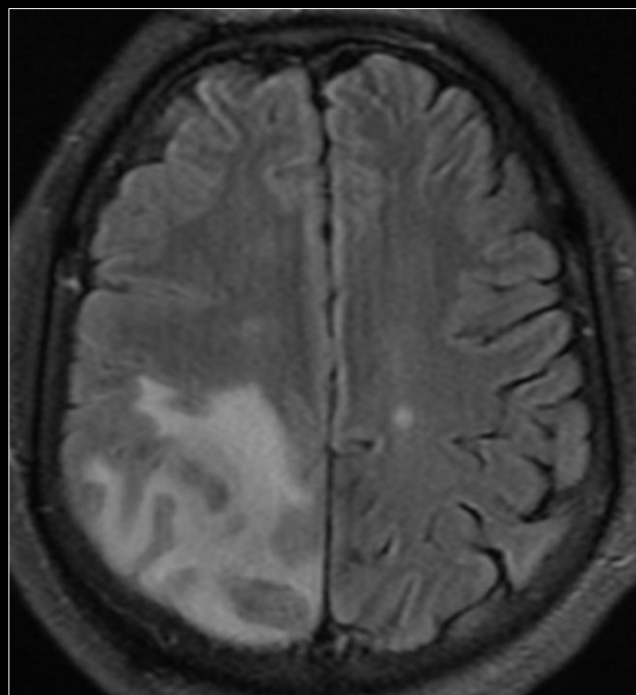
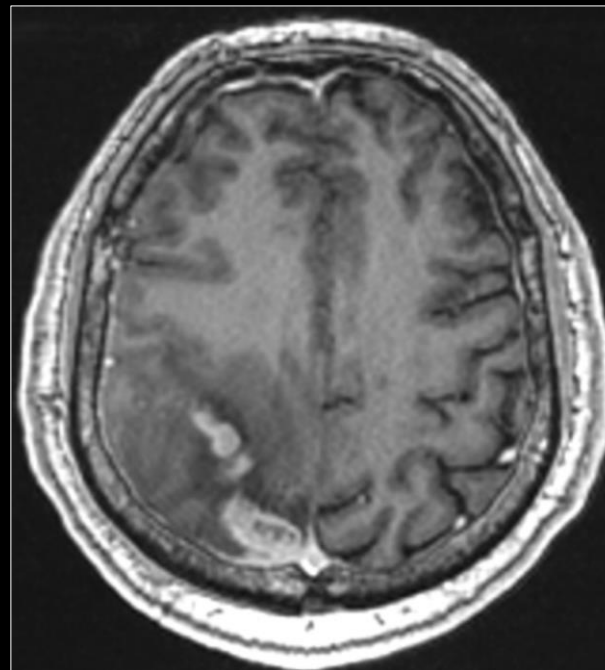
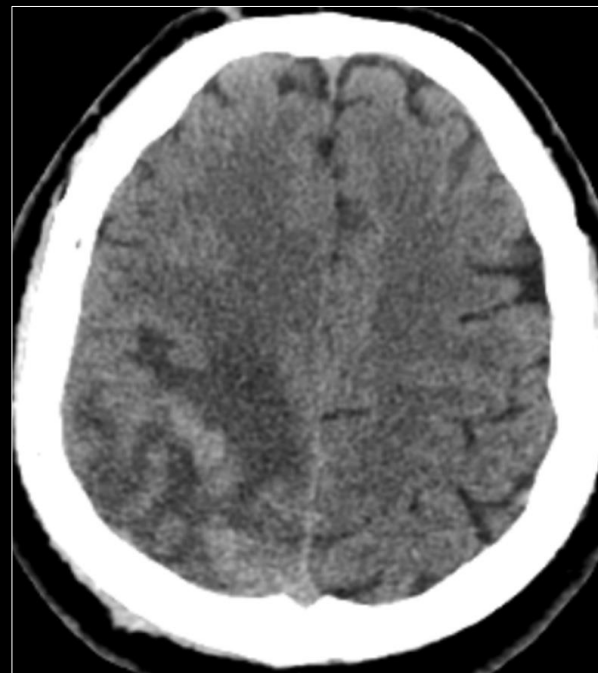
2020

Öykü: 52y e, DM'de BT'de kavernom,
3-4 yıldır sol bacakta ve kolda güçsüzlük



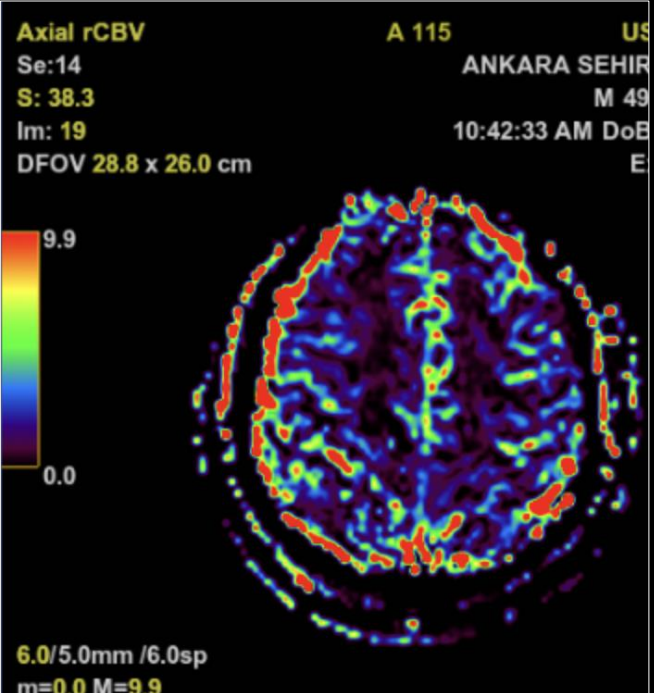
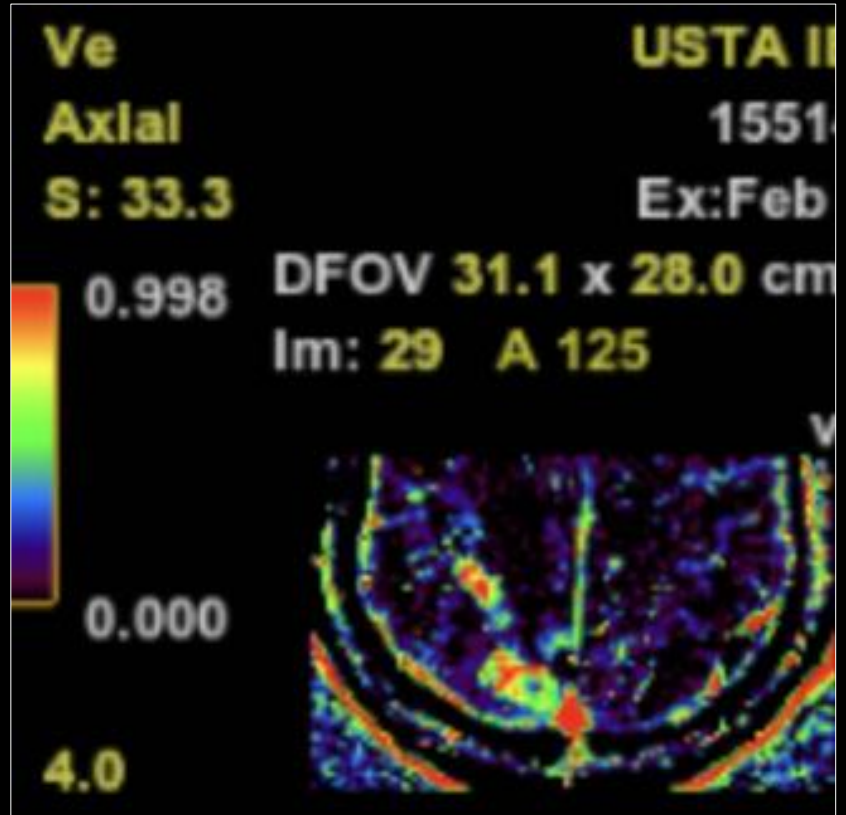
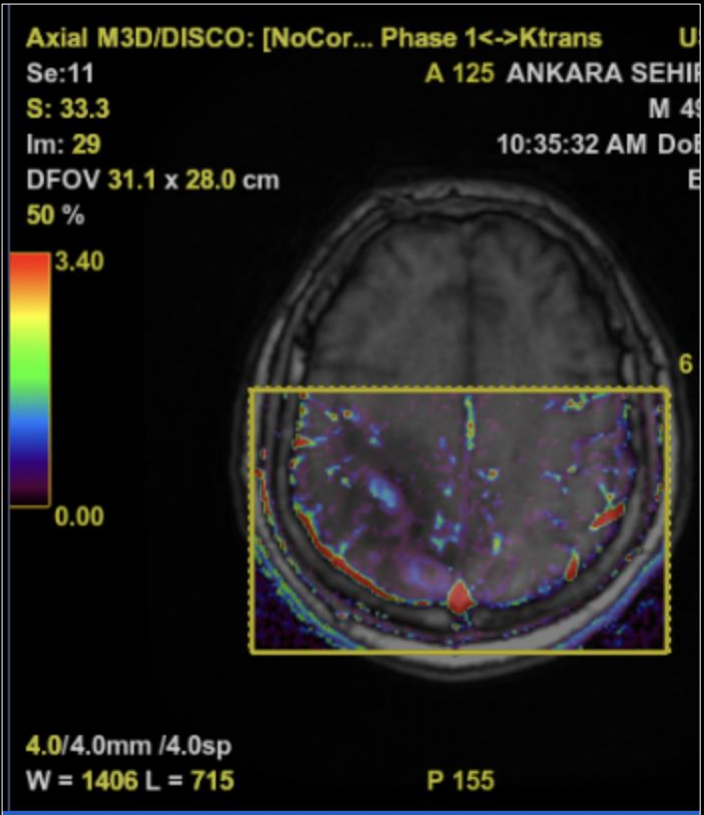
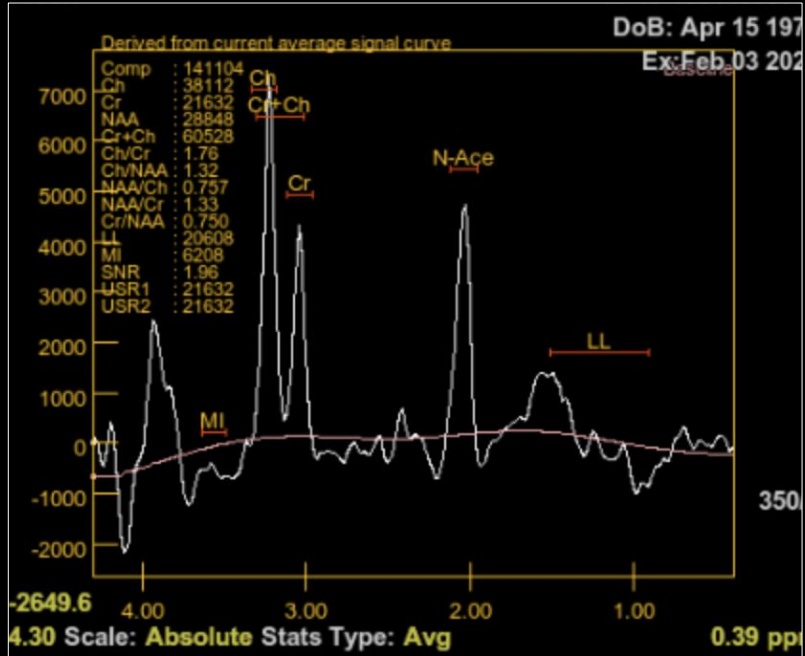


2022

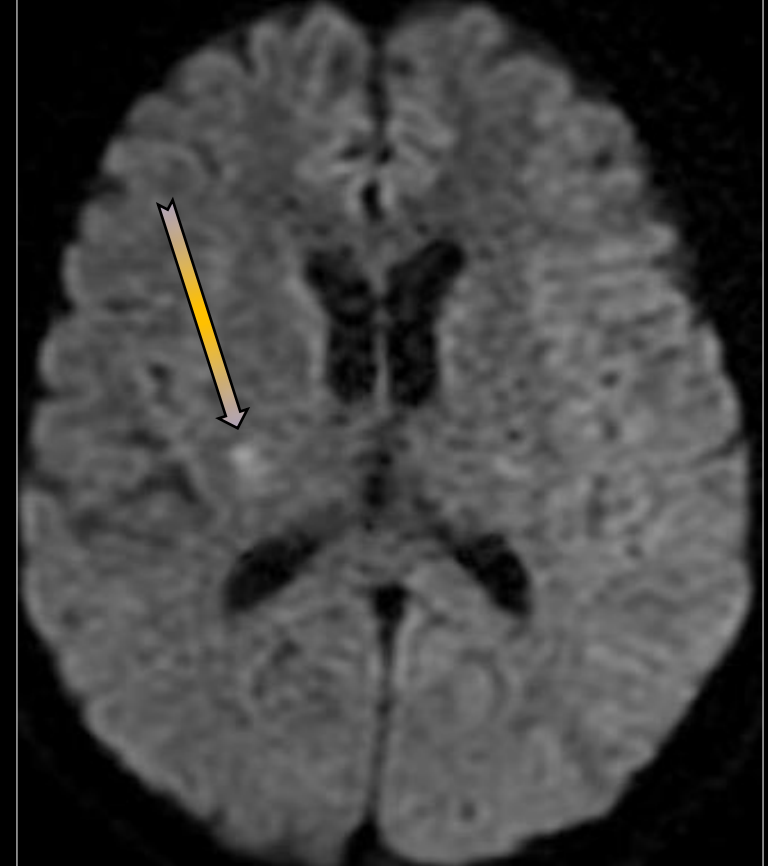
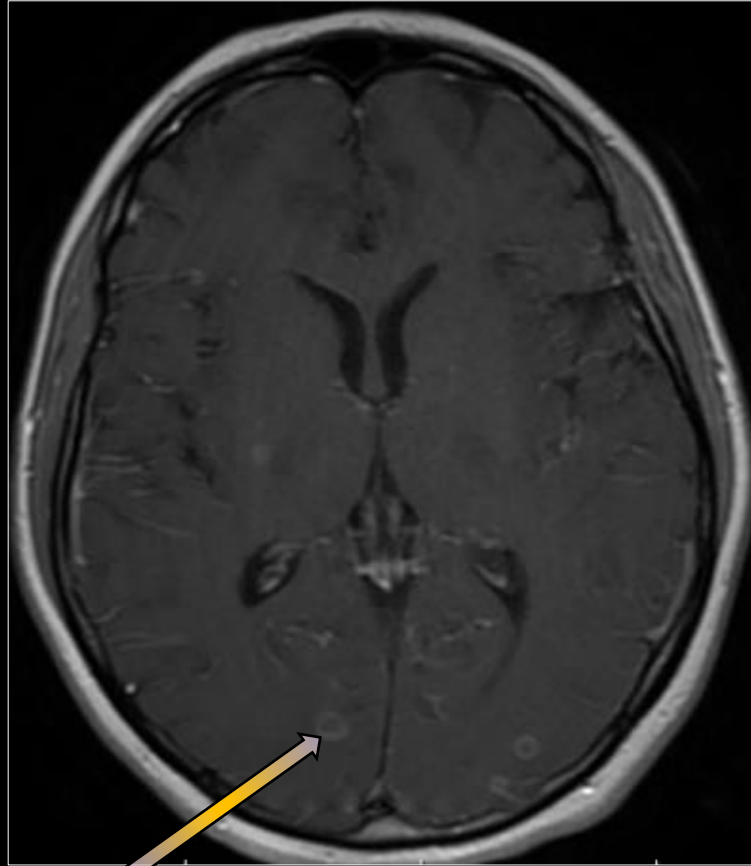
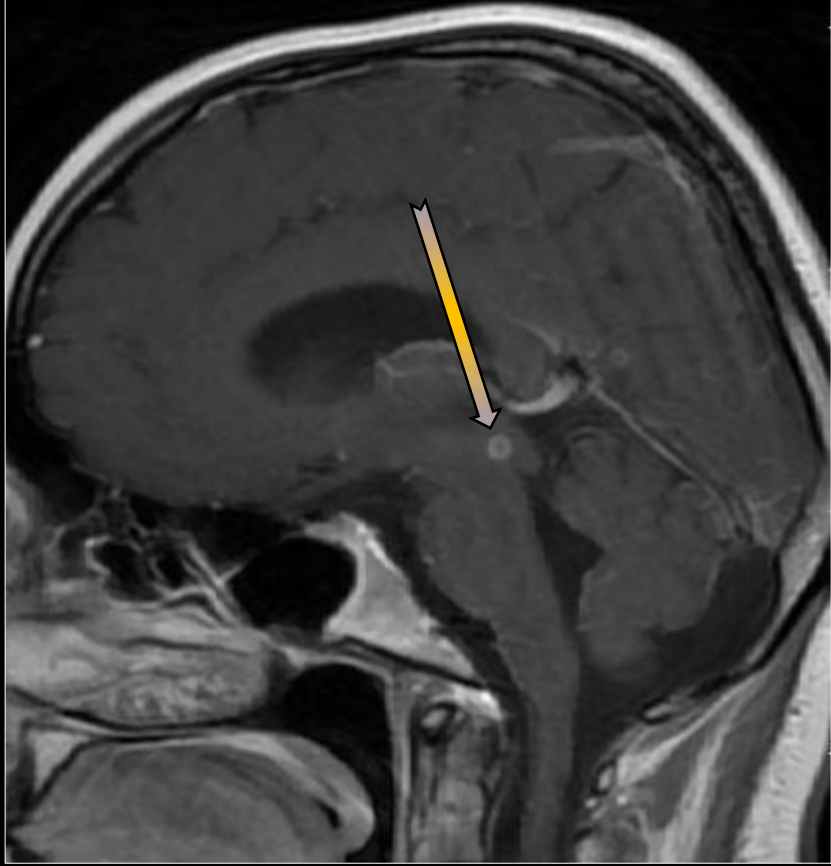

DoB: Apr 15 197

Ex: Feb 03 202



18. Milier Tüberküloz



34y e, tüberküloz öyküsü



SSS Fırsatçı Enfeksiyonlarında Nöroradyolojik Yaklaşım

Prof.Dr.Gül Hatipoğlu
Sağlık Bilimleri Üniversitesi
Ankara Bilkent Şehir Hastanesi

21 Mayıs 2024