

Case Presentation

Merve MERT VAHABI, MD

Ege University Faculty of Medicine

Infectious Diseases and Clinical Microbiology, İzmir

ESCMID Sepsis Course

EKMUD 2024

Medical History

- 26 YO/M
- Kidney transplant (2014) due to hypertension and nephrotic syndrome
- Cholecystectomy (February 2023) due to cholelithiasis
- Following cholecystectomy CMV-DNA PCR: 2760 IU/ml
- Oral valgancyclovir

Day 1, March 24

- **Symptoms**

- Cough
- Shortness of breath
- Fever

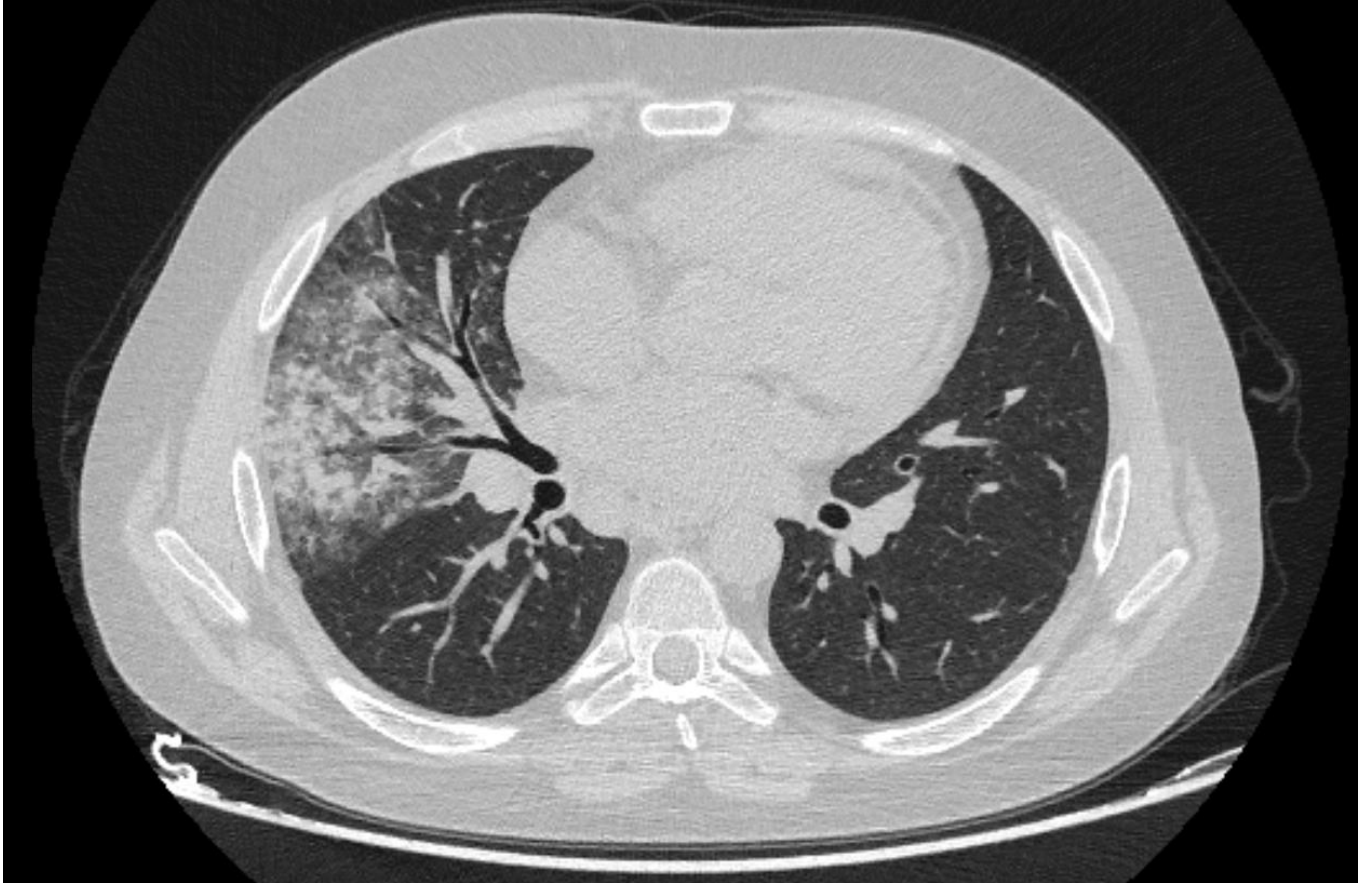
- **Physical Examination:**

- Maculopapular rash on body
- Rales in lung

- **Lab:**

- Creatinin: 5,0 mg/dL
- CRP: 39 mg/L (0-5)
- Leu: 10400/ μ L (4000-10000) neu: 94%
- Procalcitonin: 0,35 μ g/L (>0,05 μ g/L)

Thorax CT- March,24



Day 1

- **Treatment:**
- Piperacillin- tazobaktam
- Levofloxacin
- Gancyclovir

- Sputum culture → Negative

- Blood culture ??

- CMV-DNA PCR → Negative

- Nazopharyngeal swab → Negative

Blood culture, Day 3

1. Cryptococcus neoformans

(S: DUYARLI, I: ORTA DUYARLI, R:DİRENÇLİ)

Antibiyotik Adı	1. Mik/Zon Çapı
Amfoterisin B	S (0,016)
Flukonazol	N (0,25)
İtrakonazol	N (0,008)
Vorikonazol	N (0,004)
Posakonazol	N (0,012)
Anidulafungin	N (>32)

Day 3

Complications:

- Hypotension, tachycardia--> Transferred to ICU
- Sat: 94%, on room air

Laboratory:

- Creatinin: 5.3 mg/dL
- CRP: 319 mg/L
- Leu: 16710 / μ L neu:94%

Treatment:

- Meropenem
- Amphotericin B (5 mg/kg), Fluconazole (400 mg/day)
- Gancyclovir

Day 5

- **Abdomen US:**
- Transplant kidney:
 - Multiple stones and Grade 3 hydronephrosis
- Urology/ G.Surgery:
 - Nephrostomy
- C.neoformans in nephrostomy urine culture

Day 7

- Pulmonology:
 - Bronchoscopy
- CMV-DNA PCR: Negative
- Headache
- Lomber puncture ??

Day 10

- Lumbar puncture (day 8 of antifungal treatment):
 - Normal glucose and protein level
 - No leukocyte
- CSF PCR: Negative
- CSF C. neoformans-Antigen → Negative
- Bronchoscopic aspiration culture → C. neoformans

Day 12

- No growth on CSF culture
- TTE and Cranial MRI → Normal
- No fever
- CRP decreased

Day 16

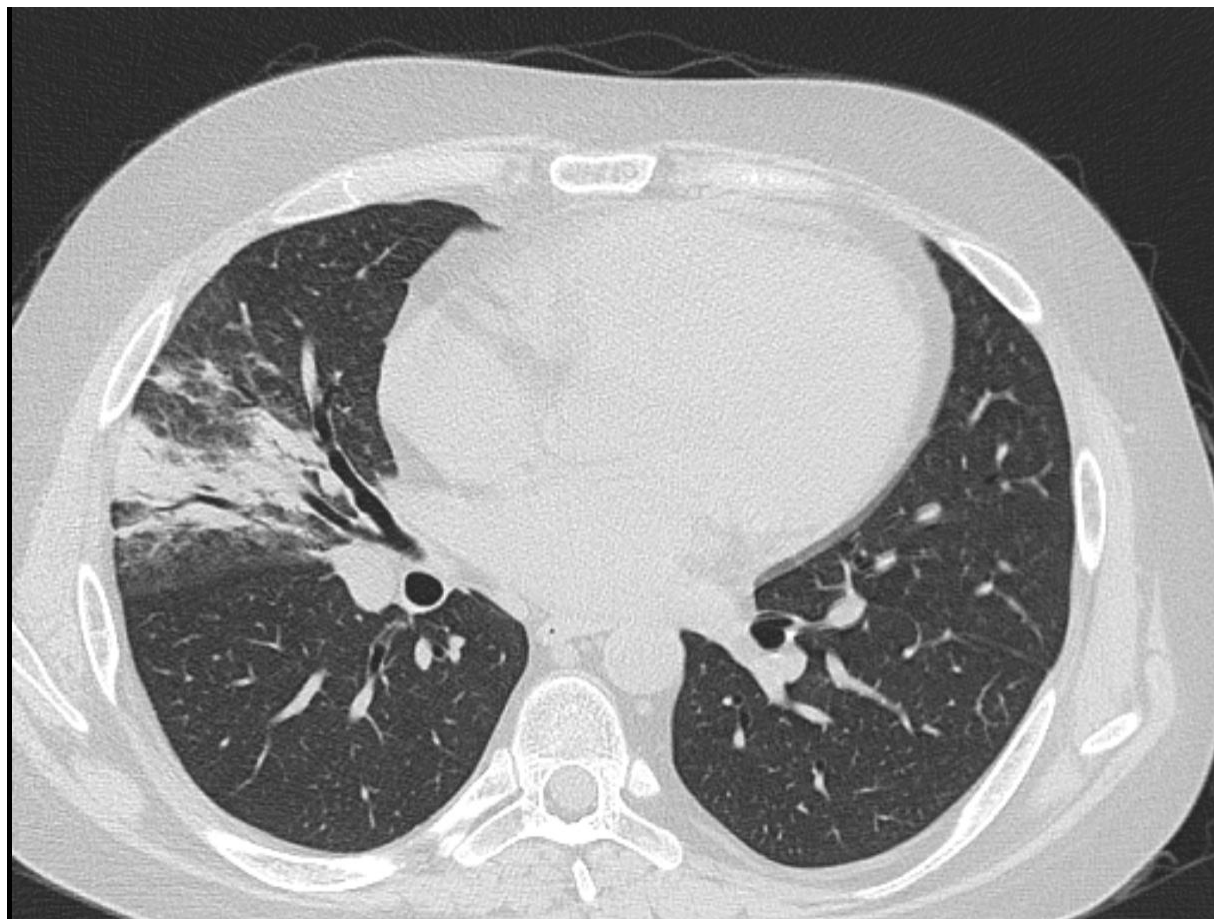
- Discontinued amphotericin B after 14 days (no growth in control cultures)
- Continued fluconazole, valgancyclovir

- CRP: 48 mg/L
- Cre: 5,1

Day 30

- Dialysis initiated from central venous cathater
- Fever
- Cough
- Oxygen support needed 2 lt/min

Thorax CT



Decrease in infiltration, increase in consolidation

Day 30

- Fluconazol was contiuned
- Meropenem was started
- Catheter and peripheral blood, sputum, urine culture, CMV DNA

Day 32

Catheter and peripheral blood culture:

- *Enterobacter cloacae* (CRE):
 - Ertapenem R MIC 8.0
 - Meropenem I MIC 8.0
 - Imipenem S MIC 1.0
 - SEF-AVI R

Final Treatment:

- Imipenem
- High-dose prolonged meropenem infusion
- Fosfomycin IV
- Fluconazole (200 mg)

Day 46

Outcome:

- Graft loss, included in routine dialysis program
- Fever response achieved, sterilized blood and urine cultures

Discharge:

- Continued outpatient follow-up with fluconazole

Q&A

- Cryptococcal infection after 15 years from kidney transplantation??
- Is CMV a risk factor for fungemia ?
- Was there any way to protect the kidney?
- Could the hospital-acquired infection have been prevented?
- How many days should we continue the antifungal treatment?



• *Thank you for your attention...*